

I have no direct financial interest in any company or product that is mentioned in this lecture.

I am on the speaker panel for:
 Alcon
 Allergan
 Abbvie Medical Optics
 Bausch + Lomb
 BVI
 TearLab

I am a consultant for:
 Alcon
 Allergan
 Abbvie Medical Optics
 BioTissue
 Lumenos
 Ocusoft
 TearLab

Marc R. Bloomerstein OD, FAAD

4

- Laura Periman MD disclosures

5

6

Dilation Vs Optomap

- The two together delivers a the highest level of Comprehensive Eye Care
- If you have to choose just one:
DILATE, DILATE, DILATE

7

Telephone Consultations

30 YO WF

Telephone symptoms:
sore upper lid, painful spot on lid

Internal Hordeolum??

Ready to Dx on telephone: decided to see the patient

8

Bacterial Conjunctivitis?

Extremely Tender Upper lid
Upper lid swelling
Excessive Mucous production

9

**Bacterial Conjunctivitis
Orbital Cellulitis?**

Tx:
PO

Augmentin PO 875 Mg Bid

Ocular
Zymaxid OS q 2 h

10

Day 2

Facial Pain Headache
Fever

Referral to PCP, R/O Orbital Cellulitis

Dx Severe Sinus infection:

Contd Meds PO (Augmentin)

Antibiotic Injection in office

Sinus infection

Lid swelling with Pain

11

- Admitted for pain control and IV antibiotics
- Proptosis, edema and pain with eye movement progressed despite broad spectrum IV antibiotics
- Urgent DCR performed



12

Chronic Unilateral Conjunctivitis

- 63 yo male with rosacea on chronic doxycycline referred with 'recurrent eye infections'
- Topical antibiotics would clear symptoms 'a little'
- Cultures grew out candida species
- Altered ENT microflora with chronic doxycycline



13

Chronic Chemosis after Blepharoplasty



14

Lid Disease- Infection

15

Treatment

- Keflex 500 Mg BID
 - Cephalexin
- Bactrim: double strength: BID
 - Trimethoprim/ Sulfamethoxazol
- Augmetin 875 mg BID
- Miboflow
- Hot compress (Written instructions)

16

Treatment

- Keflex 500 Mg BID
 - Cephalexin
- Bactrim: double strength: BID
 - Trimethoprim/ Sulfamethoxazol
- Augmetin 875 mg BID
- Miboflow
- Hot compress (Written instructions)

17

Chalazia

18

Periman IPL Protocol

- Prep: Trader Joe's or Simple micellar make up remover wipes. Commercial eyelid wipes as needed. Proparacaine, PF AFT, sterilized laser-grade corneal shields, thin-medium layer of clear ultrasound gel (take great care to avoid gel getting into eyes), applied with long edge of tongue depressor.
- Step 1: Full face rosacea pass (choose either telangiectasia or erythema based on clinical findings)
- Step 2: Toyos settings tragus to tragus, double pass
- Step 3: Switch to small light guide, treat lids, avoid eyelashes by 2mm, double pass
- Step 4: Aesthetic clean up: angioma (VL presets), facial telangiectasia (VL presets), chalazia etc. For chalazia, stack 3 extra Toyos pulses.
- Post-Procedure: remove gel with long edge of tongue depressor, gauze remove residual (again, take great care no gel gets into eyes), wipe with warm water. Pat into skin one drop Alphagan P mixed with EtaMD or Skin Medica tinted sunscreen. Place 1:16 dilution of Alphagan P in Refresh Mega into eyes.



19

Canaliculitis/Dacryocystitis

20

Treatment

- Keflex 500 Mg BID
 - Cephalexin
- Bactrim: double strength: BID
 - Trimethoprim/ Sulfamethoxazol
- Augmetin 875 mg BID
- Hot compress (Written instructions)
- MiBo Flow

21

Doctor number 3

- 68 YO female
- Pain discomfort 2 years OU
- OD > OS
- 3 rd doctor
- Treatment
- Restasis BID

22

Concretions Management

- Asymptomatic- neglect (@ 6% become symptomatic)
- Symptomatic
 - Fine tipped forceps delivery
 - 25 ga needle
 - Education R.E. recurrence

23

Allergic Dermatitis

- Elocon
- Mometasone Crème
- Lotemax ung

24

Rosacea

25

Eyelash Complications

26

EyeLash Whiplash

- Hygiene suffers
- Patients don't want to rub off their expensive extensions



27

Prostaglandin Analogs in OTC Eyelash Serums

- Aerodynamic compromise
- Upper eyelid discoloration
- MGD*
- Hyperpigmentation
- Dermatitis
- Orbital Fat Atrophy
- Iris Color Change
- CME



28

“I’ll Look Great Later and No Harm Done”

- MG toxicity from ink pigments
 - Tattoo inks may be made from titanium dioxide, lead, chromium, nickel, iron oxides, ash, carbon black, and other ingredients. Some of the pigments are industrial grade and used as automobile paint
- MG trauma
- Loss of lid margin architecture
- MG dropout
- high SPEED scores

Laura M Periman MD



29

Trauma / Abrasion

30

Corneal Abrasion

- Debridement of the Cornea
- Techniques
- Instruments
- Bandage Contact lenses
- Follow up protocols

31

Bandage contact lens

- Pros
- Cons
- Cyclo
- Antibiotic
- Nsaids

32

Follow up protocols

- Day 1
- Day 3
- If any symptoms post day 3
 - Telephone
 - Office visit

33

- Excessive pain
 - Treatment
 - Bandage
 - Nsaid
 - Narcotics
 - Cycloplegia

34

- Recurrent erosion
 - Any preventive measures

35

Recurrent Erosion

36

Recurrent Erosion

EBMD / ABMD

37

Case 2

- 50 YOF
- Woke up with discomfort
- Feels like something is in my eye

38

Case 3

- 50 YO male
- Punched in eye 3 weeks ago
- Ocular Contusion with no abrasions
- Va 20/40

39

Treatment Strategy

- ABMD
- RCE

40

Recurrent Corneal Erosion

- NaCl Ung Pm
 - Muro 128
- PF AT
 - Q 1-2 hours
- NaCl Gtts qid

41

Recurrent Corneal Erosion Long Term Therapy

- Restasis / Xiidra
 - Tid
- Fresh –Kote
 - Qid
- Lacriserts ?
- Hypertonic Vs Hypotonic AT

42

- Amniotic membrane
 - Corneal specialists – not in favor
 - Any EBM to support
- Which type
 - How long to remain in eye
 - Follow up protocol

43

- ### Treatment
- Nsaid ?
 - Delayed Corneal healing ?
 - Bandage Contact lens
 - Antibiotic??
 - How often
 - RTC daily until healed? How often?
 - Remove and fresh lens and leave in place 3 days?

44

- ### Recurrent Corneal Erosion
- Bandage Contact lenses
 - Antibiotic ung
 - Change lens how often
 - See patient how often

45

Developing a Specialty Practice

Cornea Disease

46

Epidemic Keratoconjunctivitis

47

RPS Adeno Detector

- Prospective, masked, multi-center clinical trial in U.S. and Europe
- 186 consecutive patients examined all cases of acute conjunctivitis and compared to both cell culture and PCR
- 25% of all acute conjunctivitis confirmed Adenovirus
- RPS Detector
 - 89% Sensitive vs. 91% Cell Culture
 - 94% Specificity vs. 100% Cell Culture



48

Treatment EKC

- 1 lubricants
- 2 combo antimicrobial / steroid
- 3 Steroid
- 4 Betadine
- 5 Zirgan

- Contagious ? How long

49

EKC treatment Melton/ Thomas

- Povidone- Iodine 5% (betadine)
 - Broad spectrum microbiocide
 - Indicated for "Irrigation of the ocular surface"
 - OFF LABEL USE
 - Anesthetize with proparacaine
 - Instill 1-2 drops NSAID
 - Instill several drops of betadine in eye (close eye)
 - Swap excess over lid margin
 - After one minute irrigate with saline
 - Instill 1-2 drops NSAID
 - Rx Lotemax or Zylet or Tobadex ST qid 4 days
 - No reports of adverse reactions
 - Avoid if allergic to iodine
 - Betadine 5% ophthalmic prep soln (30 ml opaque)
 - 99070 supply code

50

19yoF Red Eye OD

- Red Eye x 3 days with no pain, today was the first day with irritation
- Recently had Staph infection in leg, off antibiotics less than a week ago (Bactrim)
- VA sc 20/20- OD 20/25 OS




51

Treatment

- Zylet qid OD
- RTC 1 day
- Some improvement over the new few days, but minimal.

52




Treatment

- D/c Zylet qid OD, begin Besivance q1h OD
- Differentials?

Pt showed significant improvement, at 1-day follow up


53

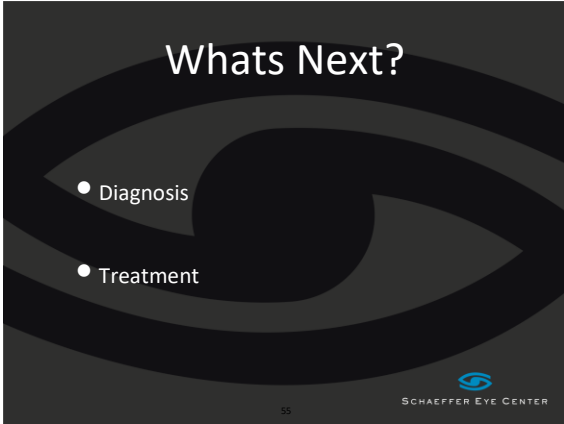

Differentials?

- Herpes Simplex Keratitis
- Adenovirus
- Solution Hypersensitivity
- MRSA
 - Remember staph in fection leg treated with Bactrim
- Nursing student

54

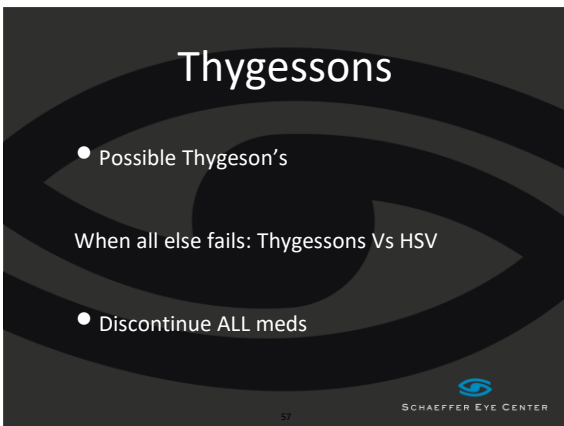




55

THYGESSONS


56



57

Thygeson's SPK


- Described by Phillips Thygeson in 1950
- Slightly elevated corneal lesions, minimal staining
- Usually bilateral, Second to third decade
- Noted corneal sensitivity decreased but not as severe as herpes
- Mild conjunctival involvement, worse with exacerbations
- Appearance similar to EKC described by Fuchs

 SCHAEFFER EYE CENTER

58

Thygeson's SPK


- Lesions in basal epithelial layer / Bowman's layer
- Debris from necrosis / degenerated epi cells
- Increased Langerhans cell density
 - Part of inflammatory response- Type II

 SCHAEFFER EYE CENTER

59

Thygeson's SPK Treatment: Anecdotal

- Cyclosporin 2% in olive oil (8 patients)
- Supratarasal injection triamcinolone (1 case-chronic 6+ years)
- Trifluridine (6 eyes)
- PRK in myopic patient had lesions recur in periphery (untreated area) vs central (treated area)
- Rimexolone 1% for reversing dendritic cell density (4 patients)


 SCHAEFFER EYE CENTER

60

Thygeson's SPK

- Steroid Use
- Loteprednol 0.2%, 0.5%
- Cyclosporine 0.05% Long Term

61



Back to the case...

- D/c All meds
- Lesions healed in 1 week
- No recurrences since October

62



Plaquenil Keratopathy

Vortex Keratopathy or Cornea Verticillata

Clinical features:

- Symptoms: the corneal changes are rarely of any visual significance.
- Signs:
 - Symmetric, bilateral, whorl-like pattern of powdery, white, yellow or brown corneal epithelial deposits
 - Appears in a vortex fashion in the inferocentral cornea and swirls outwards sparing the limbus
- Occurs in Fabry's disease and in patients being treated with a variety of drugs including amiodarone, chloroquine, amodiaquine, meperidine, indomethacin, chlorpromazine and tamoxifen.

64

Ocular Surface Disease Secondary to Systemic Disease

65

Herpes Zoster Management

- Oral antiviral agent
 - Zovirax (acyclovir) 800 mg 5x / day x 7-10 days
 - Famvir (famciclovir) 500 mg tid x 7-10 days
 - Valtrex (valacyclovir) 1000 mg tid x 7-10 days
 - Discussed with nephrologist / PCP if renal disease present

66

Ocular findings:

- Conjunctivitis/Scleritis
- Pseudodendrites
- Neurotrophic keratitis
- Iritis
- Glaucoma
- ION, vein or artery occlusion
- Nerve Palsy

67

Iridocyclitis and HZO

- Most common and most often overlooked ocular complication (43%)
- Highly elevated IOP
- Study by Thean, Hall & Stawall -*clinical Ophthalmology Dec 2001*
- 56% of patients developed glaucoma!!

68

Treatment:

- Duration?
- 7 days for most patients although newer studies (Zaal - Am J or Ophthal. Jan 2001) suggest
- 10 days for patients over age 66 due to shedding

69

Treatment: Iridocyclitis

- Pred Acetate 1% q1h or q2h or
- Durezol (Difluprednate) 0.05% with half the dosing
- Lotemax Long term
- Cycloplegia
 - Homatropine 5% bid
 - Cyclopentolate 1% bid

70

Systemic Disease- Ocular Involvement

- Herpes Simplex

71

Treatment: Epithelial Involvement

- In the past: trifluoridine - Viroptic q2h
- New replacement: **Zirgan** 5 x per day until ulcer disappears then TID x 1 week
- PO Valtrex 500mg TID
- PF artificial tears
- Follow-up (next day), day 3-4, day 7-10

72

Zirgan™ (Ganciclovir Ophthalmic Gel) 0.15%

73

Zirgan™ (ganciclovir ophthalmic gel) 0.15% Indication

Dosage and Administration

- The recommended dosing regimen for Zirgan is 1 drop in the affected eye 5 times per day (approximately every 3 hours while awake) until the corneal ulcer heals, and then 1 drop 3 times per day for 7 days.

74

Treatment: Stromal keratitis or Endotheliitis

- Durezol QID
- Pred Forte Q2H
- Cover with PO Acyclovir (400 mg bid) or Valtrex (1000mg QD) or topical (Zirgan TID)

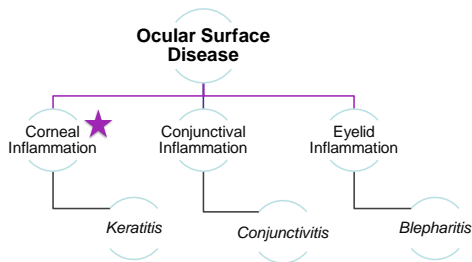
75

Restoring Corneal Clarity

- * Prokera inserted
- * Patient continued oral Valtrex 500mg QD
- * Returns 5 Days later for removal:

76

Inflammation is the Hallmark of All Ocular Surface Diseases



77

The Structure of the Fetal Amniotic Membrane

- Epithelium**
 - Metabolically active cuboidal cells with microvilli present on its apical surface
- Basement Membrane**
 - Made up type IV, V and VII collagen (also found on conjunctival and corneal basement membranes)
 - Fibronectin and Laminin
- Stroma**
 - Compact Layer provides tensile strength
 - Fibroblast Layer
 - Spongy Layer

78