When the Pressure is On Get an OCT: A Guide to Retina and Glaucoma

Jessica Steen, O.D., F.A.A.O.
NSU College of Optometry
Fort Lauderdale, FL

jessicaa.steen@gmail.com

Mark T. Dunbar, O.D., F.A.A.O.
Bascom Palmer Eye Institute
University of Miami Health System
Miami, FL

mdunbar@miami.edu

1

Mark Dunbar: Disclosure

- Optometry Consultant/Advisory Board
  - Carl Zeiss
  - Allergan
  - Regeneron
  - Iveric
  - Orasis
  - Visus
  - Tarsus
  - Avellino

Mark Dunbar does not own stock in any of the above companies

2

[illegible]

- [illegible]
- [illegible]
- [illegible]
- [illegible]

3

H[illegible]

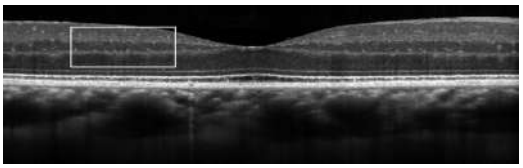

Spaide RF, Otto T, Caujolle S, Kübler J, Aumann S, Fischer J, Reisman C, Spahr H, Lessmann A. Lateral Resolution of a Commercial Optical Coherence Tomography Instrument. Transl Vis Sci Technol. 2022 Jan 3;11(1):28. doi: 10.1167/tvst.11.1.28.



4

The Evolution of OCT Imaging

- OCT has changed how clinicians look at the retina
- OCT has changed how we manage glaucoma
- The assessment of retinal abnormalities and glaucoma based on OCT imaging has advanced eye care
- OCT in Optometry practices ~ 70-85%
- As the technology has evolved -> prices continue to come down

5

Advances in SD-OCT

- Improving software
- Faster – virtual angiography
- Noise reduction/over sampling technology
- Wider and deeper scans
- Greater density in the scans
- Improvements in 3D imaging
- Enhanced depth imaging – imaging choroid
- Progression analysis software

6

Resolution of SD OCT

- ~ 5 microns

7

Understanding the Fundamentals

8

Don't Make It More Complicated Than it Needs to be

- Many macular disease conditions have a "signature" OCT feature
- Learn what those are and the diagnosis and interpretation becomes easier

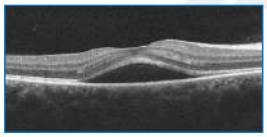

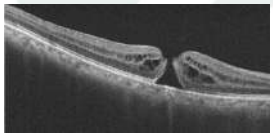

9

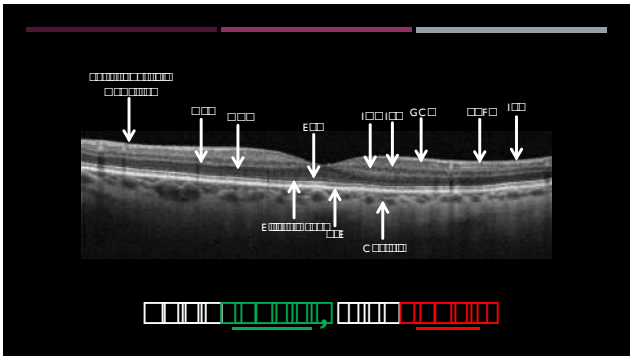

10

Where is the Fluid?

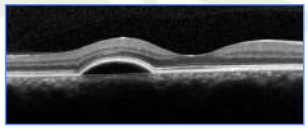

11

Central Serous Chorioretinopathy (CSR)

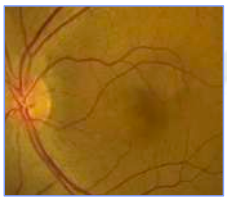

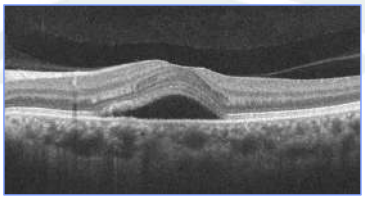

44 y/o Female: Notes blur in the LE X 1 mo BCVA: 20/25

12

Diabetic Macular Edema (DME)

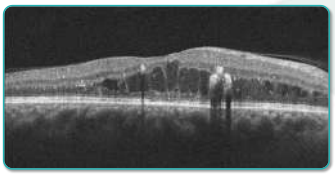

SD-OCT of a retina with DME

Color Fundus photo with DME

13

The Macula in Diabetes

14

The Macula in Diabetes

- Is there retinopathy?
- Is there retinal thickening?
- Is there fluid?
- How close is it to the macula?

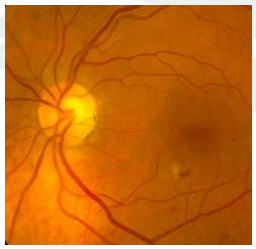

15

Macular Edema

- Thickening of the retina
- Secondary to leaky microaneurysms
- **90% of visual loss in diabetes**

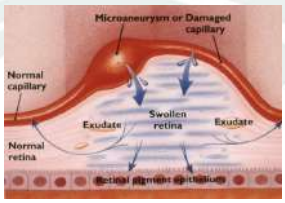

16

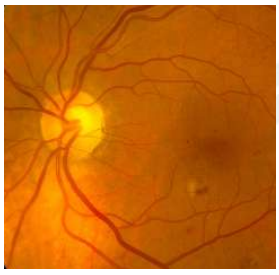

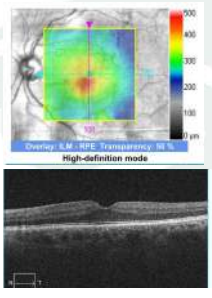

17

CSME

- Retinal thickening within 500 microns from the center of the FAZ
- Hard exudates associated with retinal thickening 500 microns from center of FAZ
- Zones of retinal thickening > 1 DD in area, any part of which is 1 DD from the center of the fovea

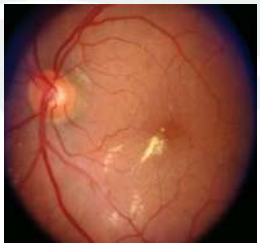

18

How we diagnose diabetic macular edema is changing

ETDRS definition has been modified in the era of OCT and anti-VEGF therapy

19

2017 DME Classification:

Center Involved of Not?

- ETDRS definition of "clinically significant macular edema" modified in era of OCT
- Randomized clinical trials of anti-VEGF agents used presence of DME in **OCT central subfield**

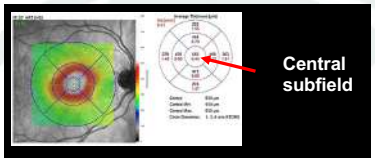

Nguyen, Quan Dong, et al. "Ranibizumab for diabetic macular edema: results from 2 phase III randomized trials: RISE and RIDE." Ophthalmology 119.4 (2012): 789-801.
Brown, David M., et al. "Intravitreal aflibercept for diabetic macular edema: 100-week results from the VISTA and VIVID studies." Ophthalmology 122.10 (2015): 2044-2052.

20

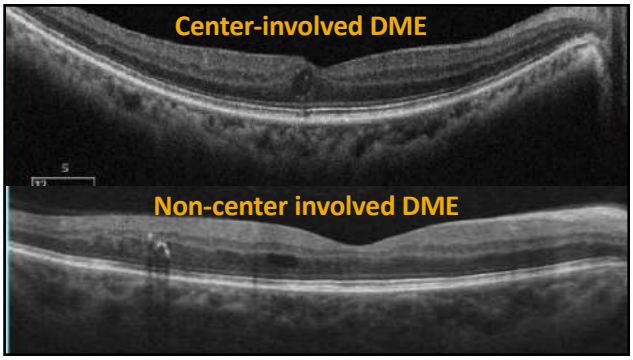

21

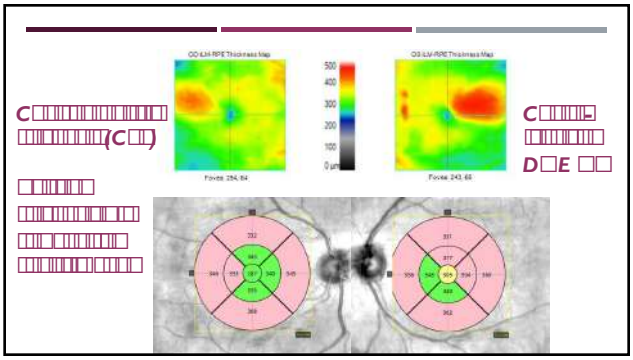

22

OCT Angiography (OCTA) is a great non-invasive tool to view the microvascular

23

OCT Angiography (OCTA)

The Basic Idea of How it Works:

- **Capturing motion** in the retina
- Scans at 68,000 A-scans per second
  - Traditional SD OCT scan at 28,000 to 40,000 A- scans per second
- Compares repeat scans acquired at the same position in the retina to look for changes - motion

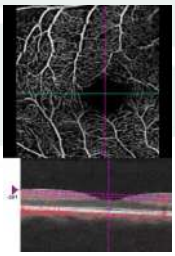

24

OCT ANGIOGRAPHY

- The only thing that moves in the retina over time are red blood cells
- Take the ‘difference’ between multiple B scans at the same location to produce a ‘decorrelation signal’

OCT ANGIOGRAPHY

- En face flow formation and cross sectional structural information
- Not a replacement for FA/ICG
  - Provides new information
- Valuable for detection of choroidal and retinal neovascularization, macular ischemia, segmentation of the deep and superficial capillary plexi—and maybe early glaucoma?

MACULAR ISCHEMIA

- Vision loss either due to fluid within in the macula or a poorly perfused macula
  - Macular ischemia in the absence of DME/hemorrhage/exudate
  - Enlargement of the foveal avascular zone is a sign of ischemia

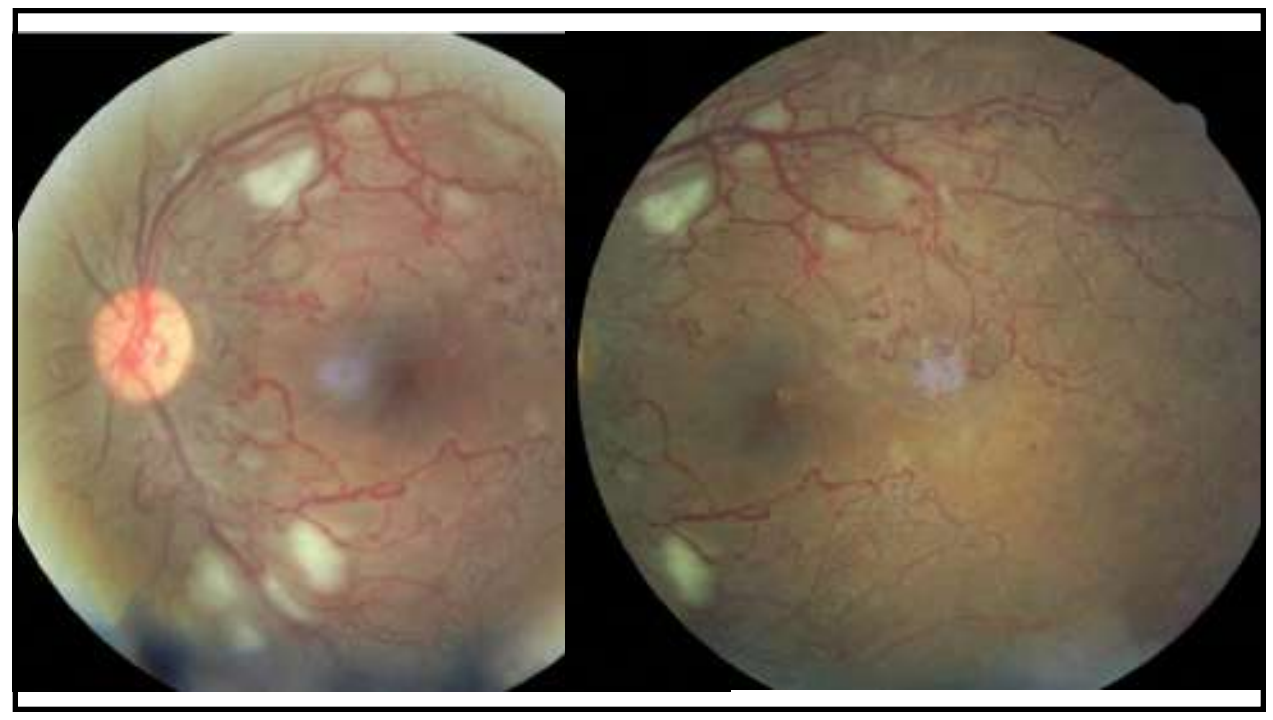

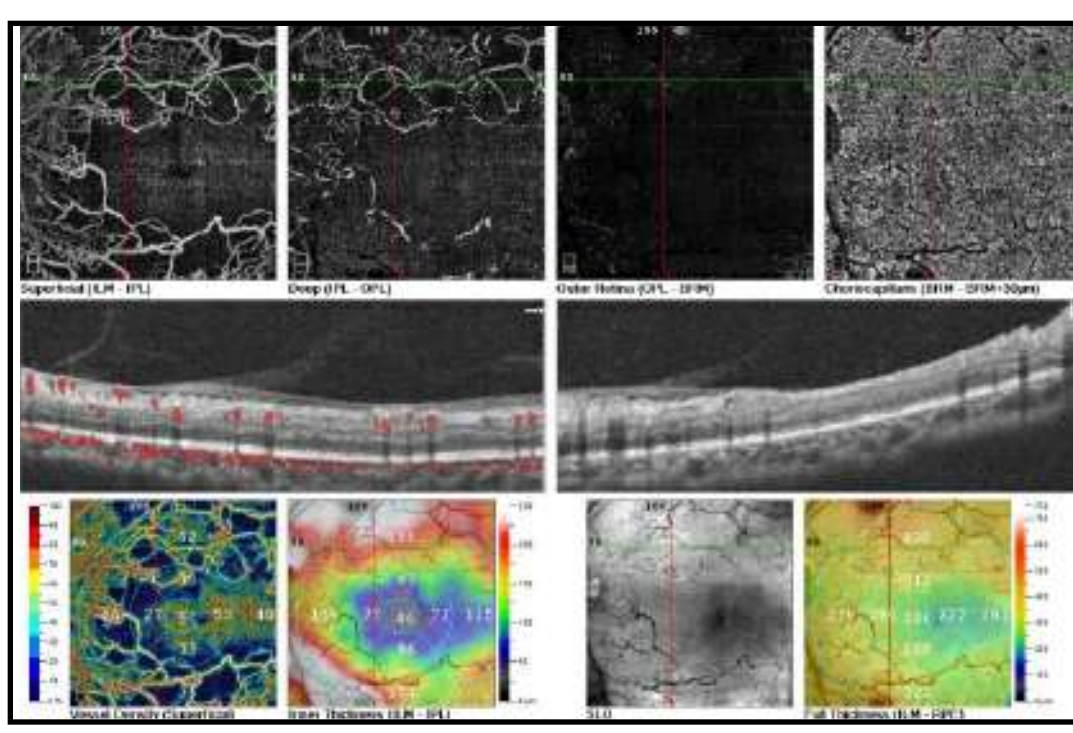

OS
20/400

ISCHEMIA IN DIABETIC RETINOPATHY

- Cotton wool spot
  - Really not an “infarct”

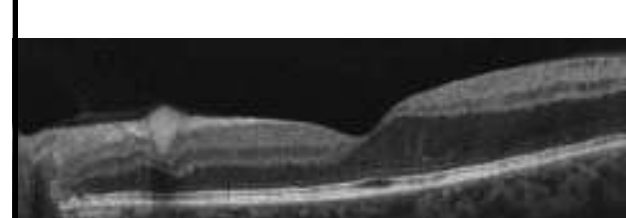

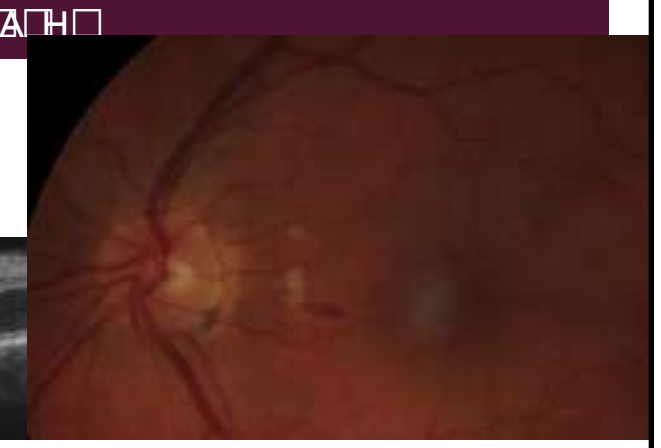

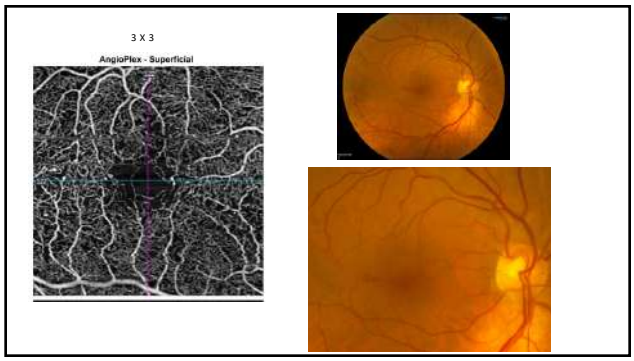

31

32

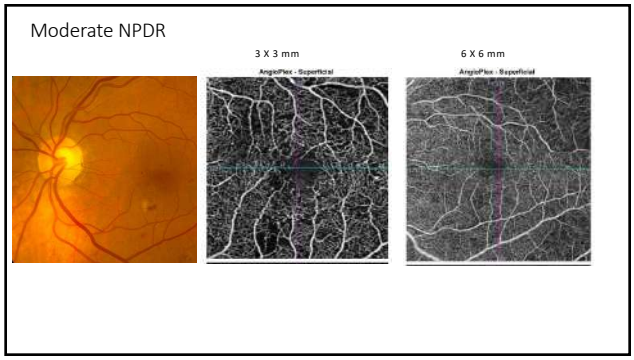

33

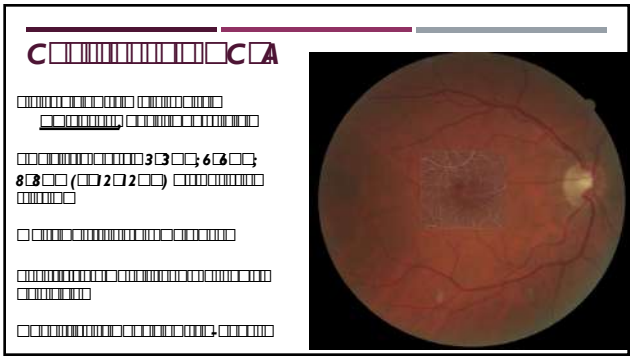

34

Risk Factors for Progression to Wet AMD

- Traditionally based on clinical appearance
- Intermediate AMD
  - Large drusen > 125 microns
  - RPE mottling/pigmentary abnormalities
- **Risk of conversion to wet AMD over 5 years > 50%**

35

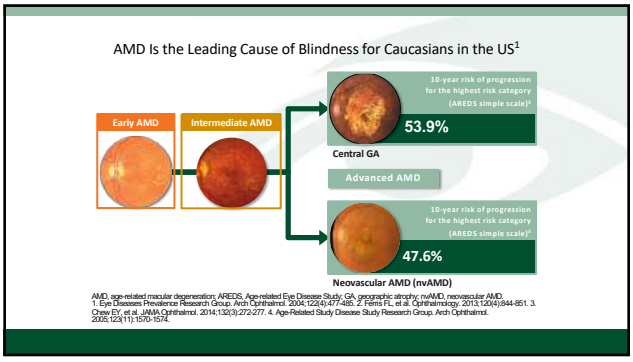

36

OCT findings in dry AMD can be predictor for progression to GA or CNV

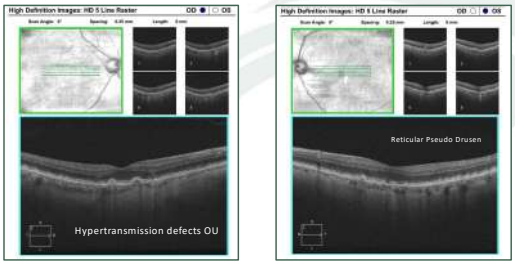

37

OCT Biomarkers May Help Predict Conversion to GA or Wet AMD



Review Article

OCT Biomarkers in Neovascular Age-Related Macular Degeneration: A Narrative Review

Cristina Metrangolo, Simone Donati, Marco Mazzola, Liviana Fontanel, Walter Messina, Giulia D'Alterio, Marica Rubino, Paolo Radice, Elias Presti and Claudio Azzolini

Review

Retinal Progression Biomarkers of Early and Intermediate Age-Related Macular Degeneration

Rita Flores, Ângela Carneiro, Sandra Tenreiro and Miguel C. Seabra

38

OCT Biomarkers May Help Predict Conversion to GA or Wet AMD

- Drusen volume
- Increased drusen height
- Abnormal thinning of the RPE layer

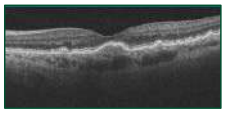

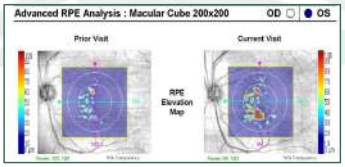

39

OCT Biomarkers May Help Predict Conversion to GA or Wet AMD

- Hyper-Reflective Foci (HRF)
- Retucular pseudo drusen
- Incomplete Retinal Pigment Epithelial and Outer Retinal Atrophy (iRORA)
  - Without RPE loss
  - Replaces "Nasacent GA"
- Hyper-transmission defects
- OCT-Reflective Drusen Substructures

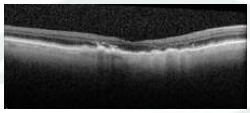

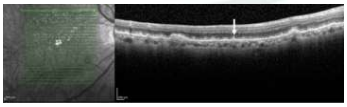

Life **2022**, *12*, 36. https://doi.org/10.3390/life12010036 https://www.mdpi.com/journal/life

40

OCT Biomarkers May Help Predict Conversion to GA or Wet AMD

<u>Hyper-Reflective Foci (HRF)</u>

- Extracellular pigment granules and outer segment debris (outer HRF)
- May also represent displacement and clumping of degenerated RPE cells
- AREDS2 study: Patients with HRF had 5 X increased risk of progression to GA at 2 years vs. controls

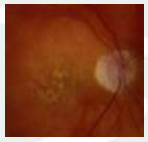

41

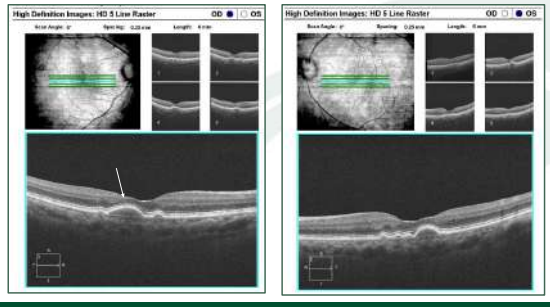

42

3/26/18: Conversion from Dry to Wet AMD OU

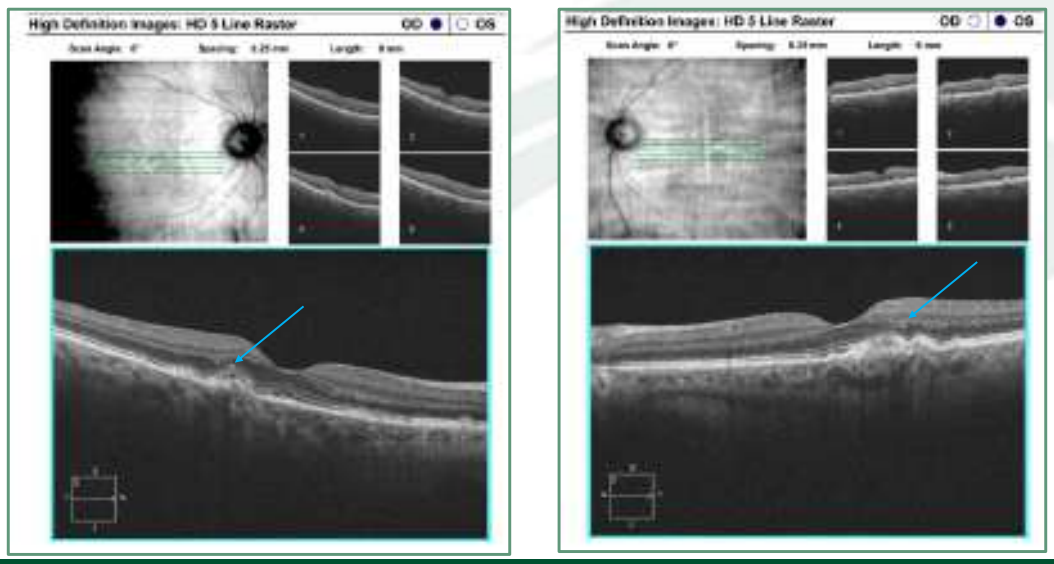

43

11/30/2021: Multiple anti-VEGF injections OU

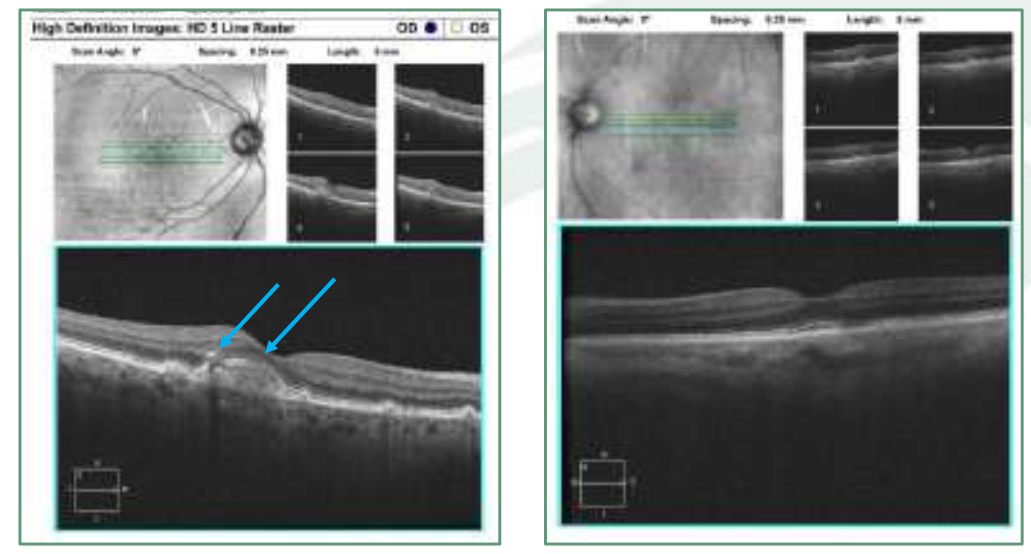

44

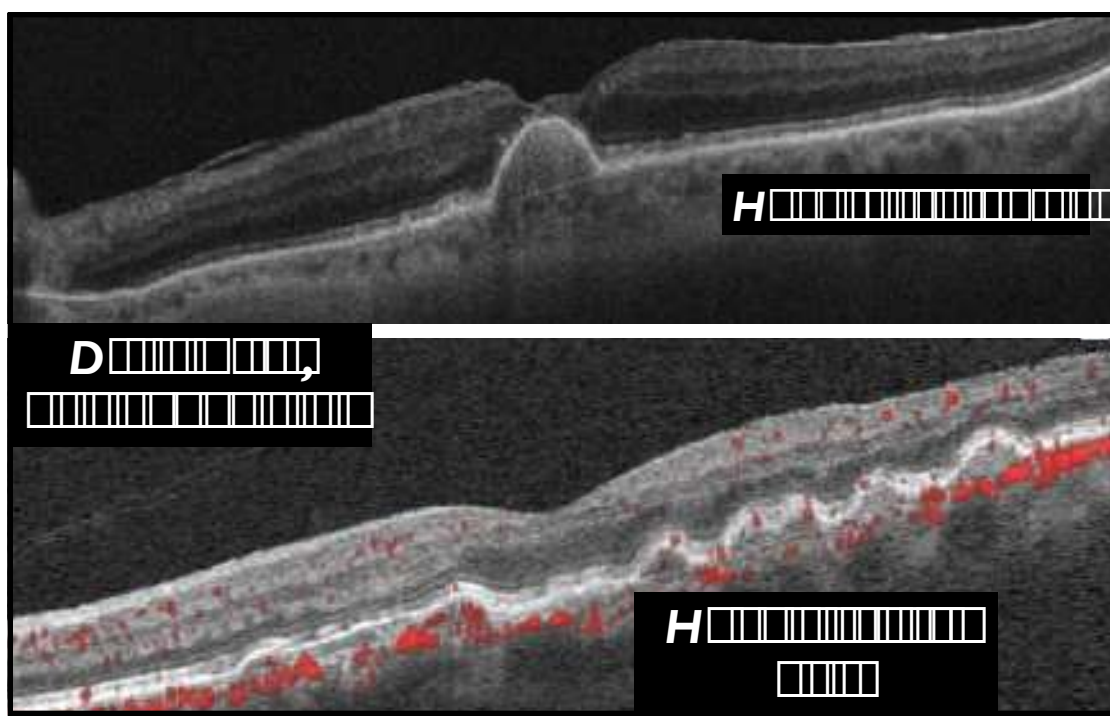

45

Hyperreflective Retinal Foci (HRF)

- Secondary to:
  - DR/DME, RVO, AMD, CSR, Uveitis, MacTel; IRD
- Most likely activated inflammatory microglia cells
- **Biomarker for disease progression**

Lara-Medina FJ, Esteban O, Bartolome I, Ispa C, Mateo J, and Ascaso FJ. "New landmarks, signs, and findings in optical coherence tomography." Clin. App. of OCT in Ophthamol. Feb 2019; 10.5772
Coscas G, De Benedetto U, Coscas F, Li Calzi CI, Vismara S, Roudot- Thoraval F, et al. Hyperreflective dots: A new spectral-domain optical coherence tomography entity for follow-up and prognosis in exudative age-related macular degeneration. Ophthalmologica. 2013;229(1):32-37
Ogino, Ken et al. "Characteristics of Optical Coherence Tomographic Hyperreflective Foci in Retinal Vein Occlusion." Retina (Philadelphia, Pa.) 32.1 (2012): 77–85.
Fragiotta, Serena et al. "Significance of Hyperreflective Foci as an Optical Coherence Tomography Biomarker in Retinal Diseases: Characterization and Clinical Implications." Journal of ophthalmology 2021 (2021): 6096017–10.

46

Reticular Pseudo Drusen

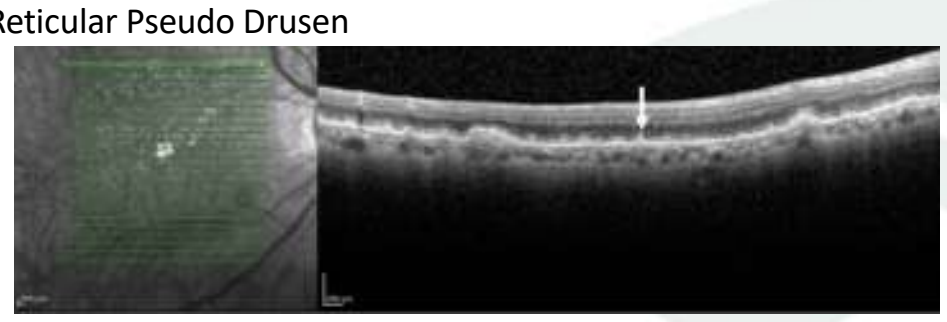

- Subretinal collections of granular, interlacing, hyper-reflective material located above RPE
- Commonly found in the superior macula or close to superotemporal arcade
- Undergo a characteristic lifecycle of growth, invasion into the ellipsoid zone, and finally regression
- Reticular pseudodrusen is associated **with an additional 2-6-fold increased risk of progression to nAMD or central GA**,
  - Risk of progression higher for reticular pseudodrusen located outside the macula

47

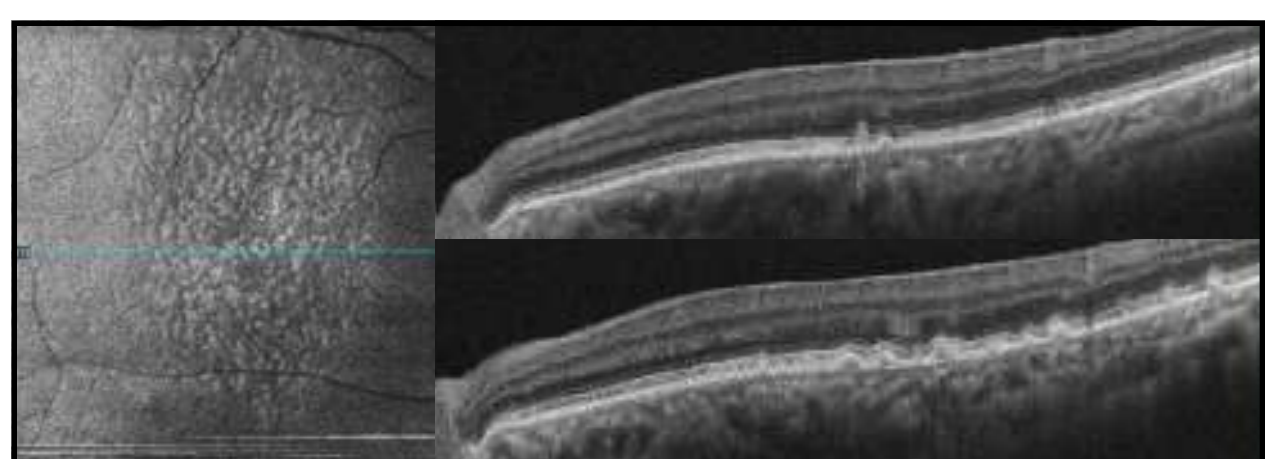

Nassisi M, et al. OCT risk factors for development of late age-related macular degeneration in the fellow eyes of patients enrolled in the HARBOR Study. Ophthalmology 2019;126:1667-1674.

48



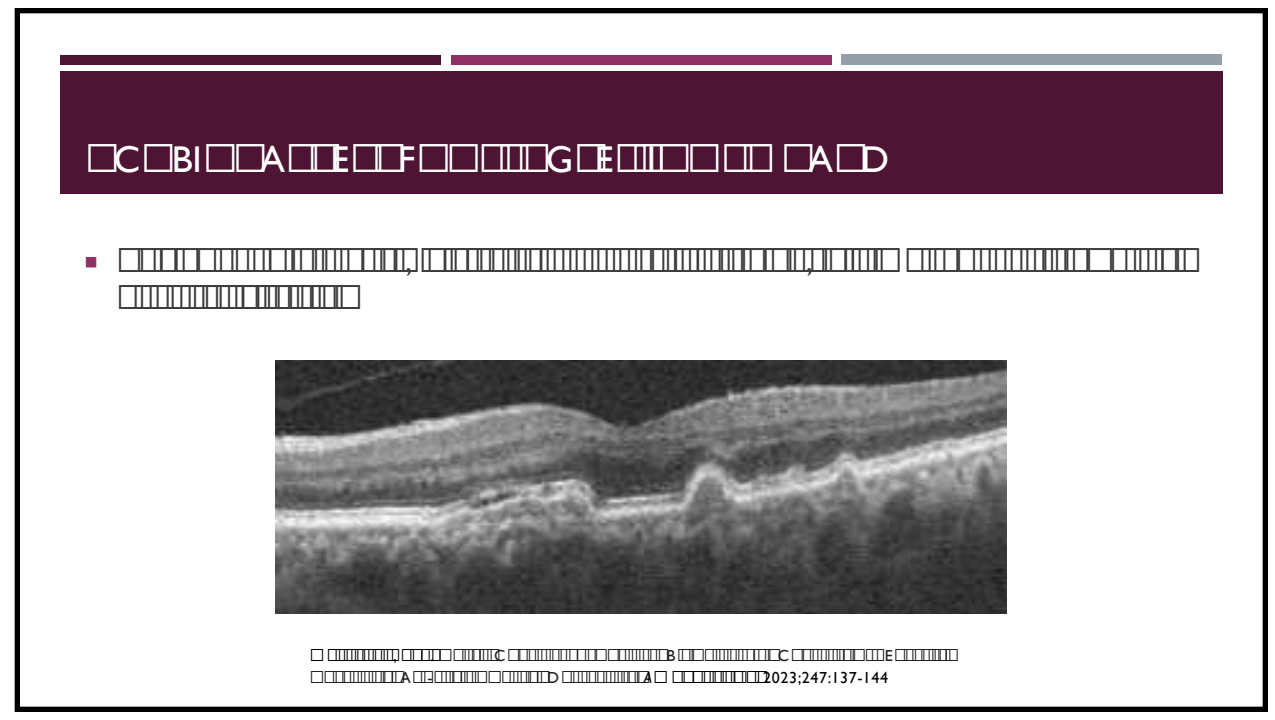

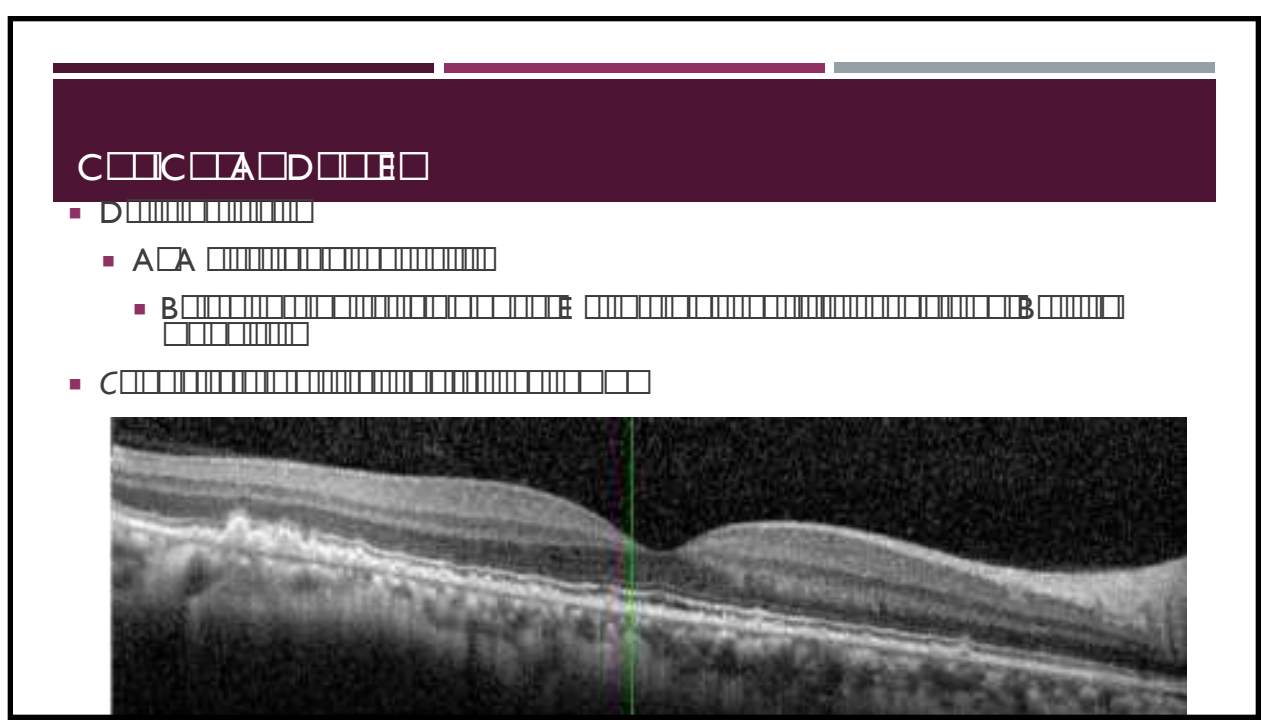

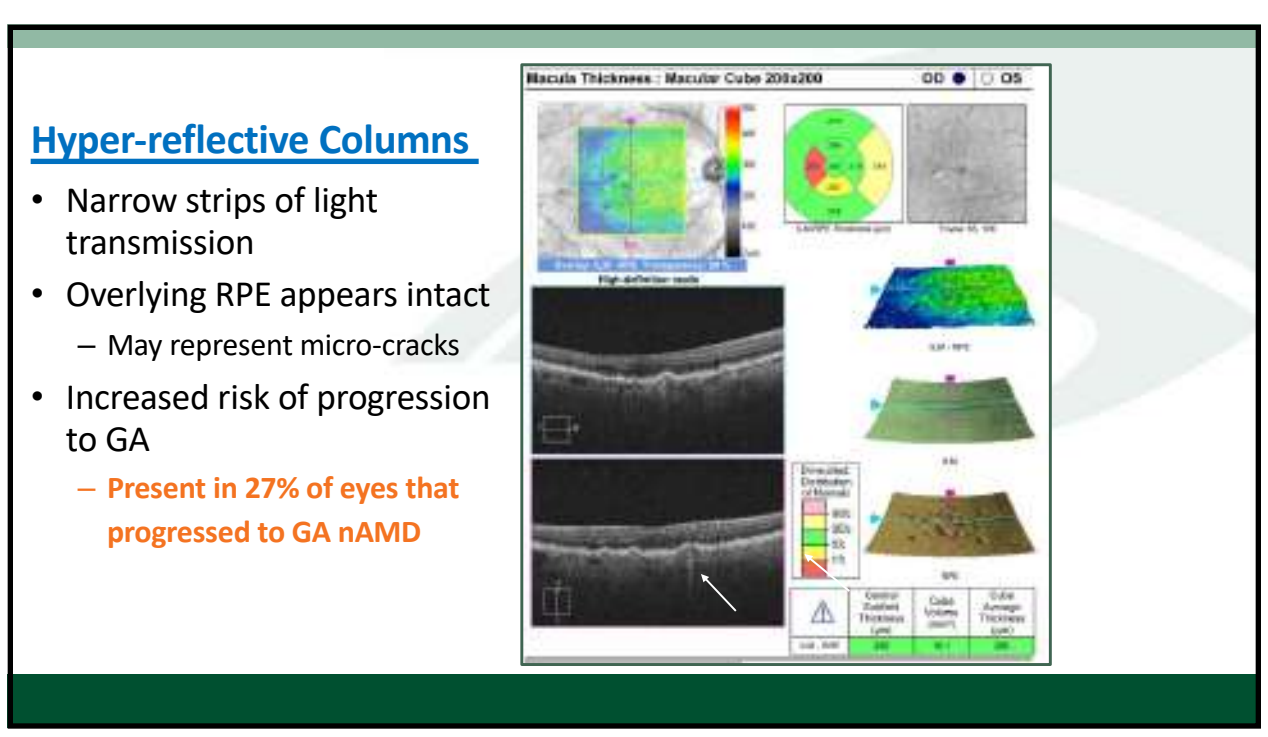

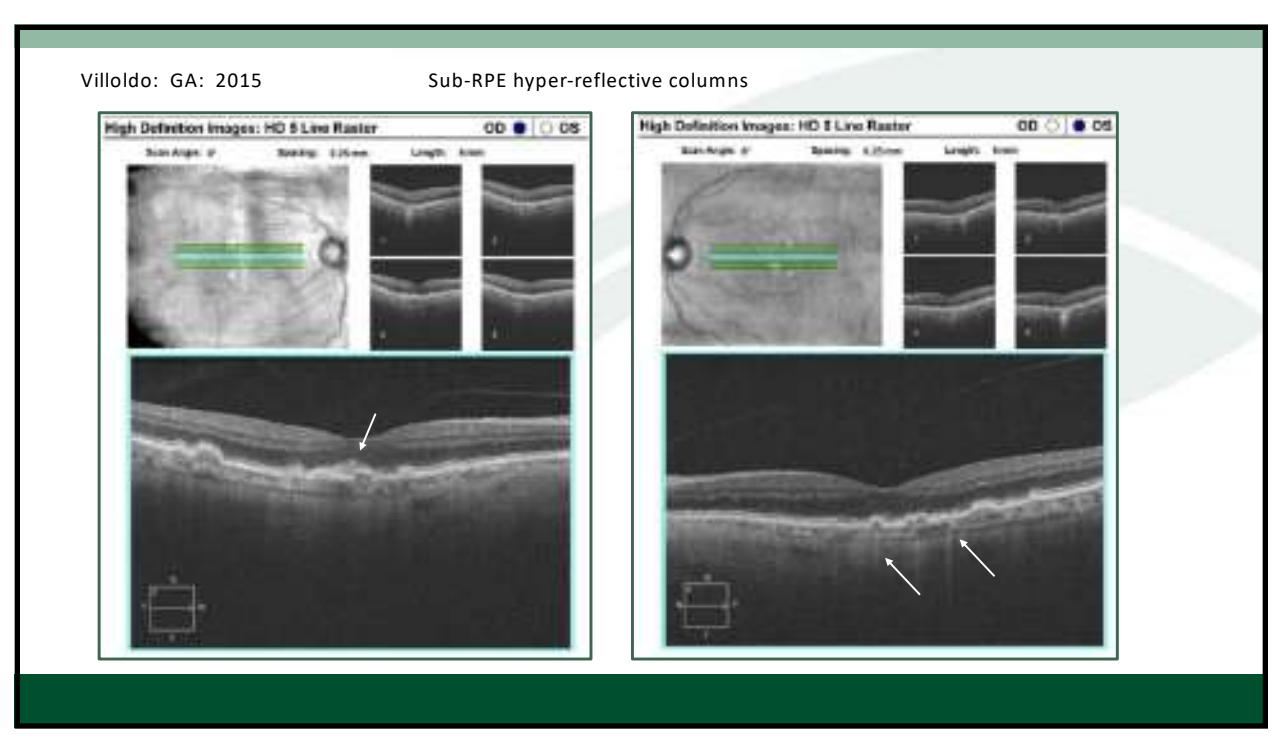

□□B□E□I□A□D□□□E□□ID DE□□□□□

- Distinctive type of drusen aka reticular pseudodrusen
  - Subretinal space extending to the outer segments of photoreceptors
- Not just drusen above the□□E
  - Include immun□reactive cells macrophages microglia
    - Impact dark adaptation choriocapillaris flow impairment
- Increased risk of progression to late stage \□D
  - Finger et al 014

OCT BIOMARKERS FOR □□□G□E□□□□TO □A□D

- Thick double layer sign intraretinal hyperreflective foci fellow eye exudative macular neovascularization

Wakatsuki Y et al Optical Coherence Tomography Biomarkers for Conversion to Exudative Neovascular Age-related Macular Degeneration m J Ophthalmol 023;247:137-144

C□□IC□□A□D□□□E□

- Drusen subtype
  - A□A basal laminar deposits
    - Between the basal lamina of□□E and the inner collagenous layer □Bruch's membrane
- Can progress to geographic atrophy and MNV

Colloid drusen

Hyper-reflective Columns

- Narrow strips of light transmission
- Overlying RPE appears intact
  - May represent micro-cracks
- Increased risk of progression to GA
  - Present in 27% of eyes that progressed to GA nAMD

Villoldo: GA: 2015

Sub-RPE hyper-reflective columns

C□□□A □□□□A

- CA□ (□□□□□□□□□□□□□□□□□□□□□□□) □□□□□□□□
  - C□□□□□□□□□□□□□□□□□□□
- C□□□□□□E □□□□□□□□□□□□ (□□□A) □□□□□□□□□□A□□
  - >= 250μ□ □□□□□□□□□□□□□□□□□□ □□□□□□□C□B-□□□; □□□□□A (□□□□□□□□)
  - □□□□□□□□□□□□□□□E □□□□□□□□□□□250μ□

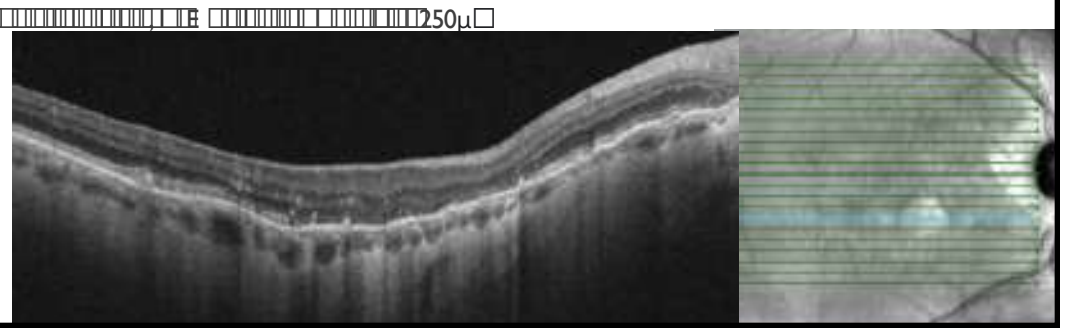

55

Table 1. Progression biomarkers in AMD.

Biomarker	Imaging Findings	Mechanism(s)	Prevalence in AMD%	Expected Progression (OR [1])
Drusen volume	Baseline drusen volume	Displacement or deterioration of photoreceptor layer	ND [2]	1.31 risk of progression to nAMD (for each 0.1 mm³ of drusen volume increase) [36]
RPE-Drusen complex (DC) Advanced analysis	RAT [3]	RPE suffering and drusen regression	ND [2]	1.32 risk of developing central GA (for each 0.001 mm³ increase in RAT volume) [36]
HRF	Punctate hyperreflective lesions	Anterior migration of fully pigmentated RPE cells, inflammatory or microglia cell and calcification	50% in AMD	5 risk of 2-year progression to GA [27]
SDD	Small yellow deposits: reticular, ribbon-like or interdigitated	Dysfunction of cholesterol homeostasis, retinoid processing or choroidal hypoxia [55]	32% to 79% in AMD patients	2.24–3.4 risk of progression to advanced disease [1,42]
iRORA	Subsidence of the OPL [4] and INL [5] with a hypo-reflective wedge	New onset of atrophy (nascent atrophy)	7% in intermediate AMD [56]	5.2 risk of progression to central GA [43]
Hypertransmission	Columns or strips of hyperreflectivity	Deficiencies within RPE layer	27% in AMD patients [48]	ND
ODS	Internal heterogeneity	Metabolic instability	24% in soft drusen	5.6 risk of progression to new atrophy onset [57]
Non exudative Retinal neovascularization	Neovascular lesion with no fluid	Protective mechanism against ischemia	6.25 to 27% in the fellow eye of exudative AMD [54]	1.21 risk of progression to exudative AMD at 1 year [52]

[1] Odds ratio; [2] not determined; [3] RPE Abnormal thinning; [4] Outer Plexiform Layer; [5] Inner nuclear Layer.

56

Double Layer Sign

- Shallow, irregular retinal pigment epithelium (RPE) elevation, or **SIRE**
  - Stemmed from the double-layer sign initially described in polypoidal choroidal vasculopathy.
- When the RPE is elevated due to (macular neovascularization), the underlying hyperreflective Bruch's membrane becomes visible
  - Creates 2 hyperreflective lines or a double-layer sign
- In patients with nonexudative AMD - SIRE may predict that 1 in 4 of these patients have an underlying MNV that is not yet exudative
- Features of SIRE include:
  - length of more than 1000 mm
  - RPE elevation < less than 100 mm (resulting in shallow morphologic features),
  - Irregular overlying RPE layer,
  - Nonhomogenous reflectivity

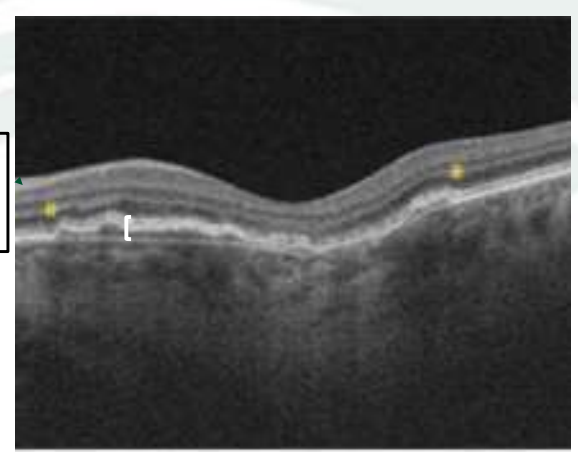

57

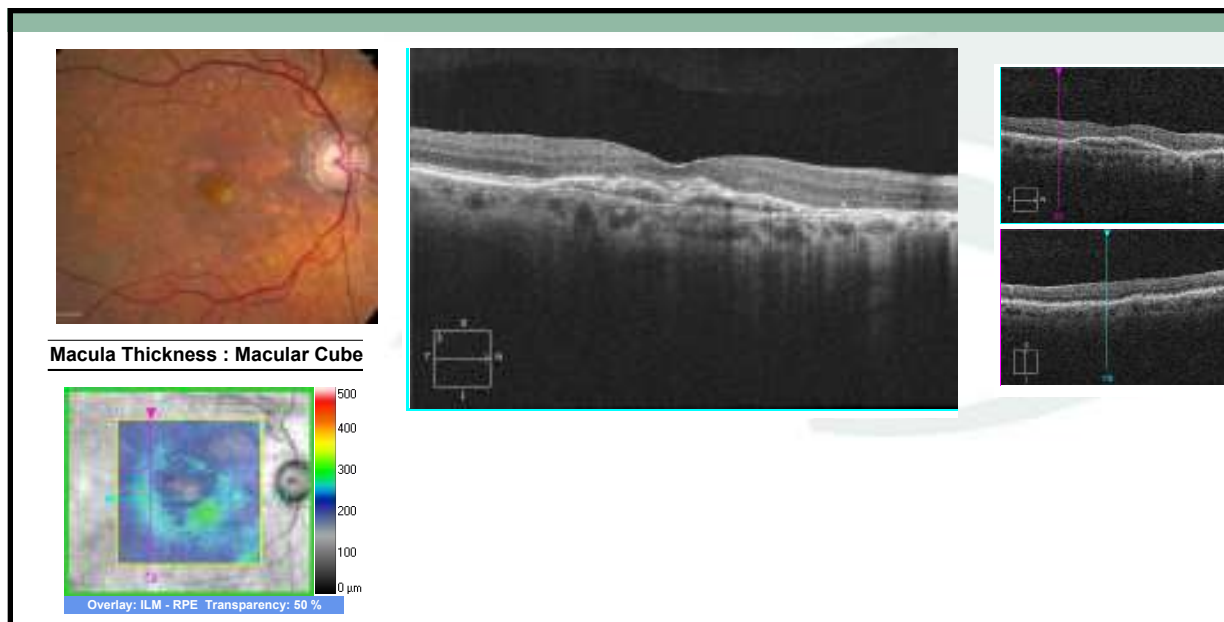

58

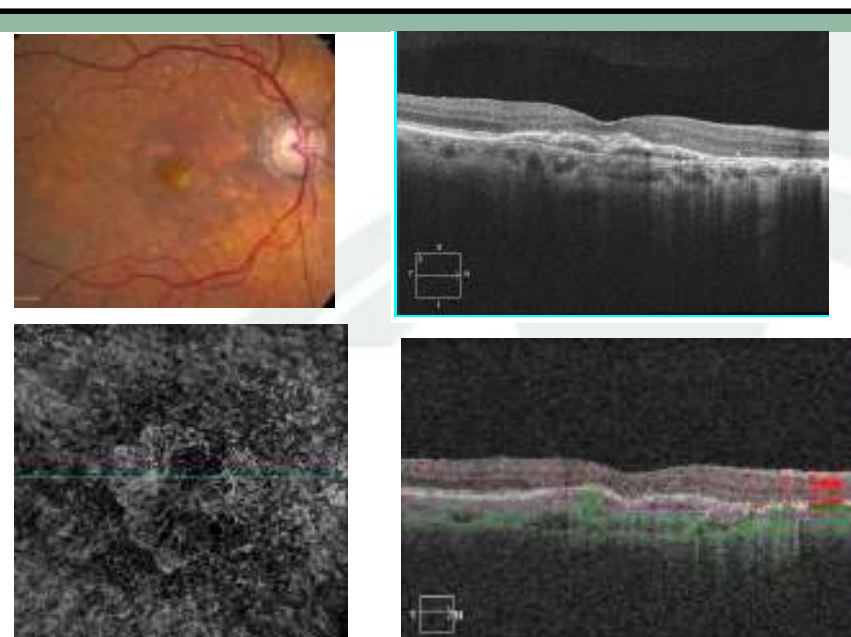

59

Pay Attention to the Vitreoretinal Interface

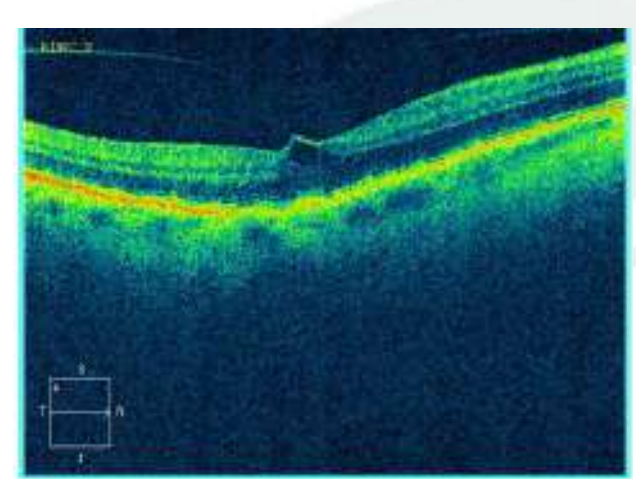

60

5 Diseases Arising from the Vitreomacular Interface (VMI):

- Vitreomacular traction (VMT)
- Full Thickness macular hole (FTMH)
- Lamellar macular hole
- Epiretinal membrane (ERM)
- Myopic macular schisis

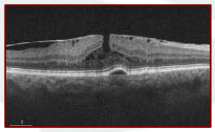

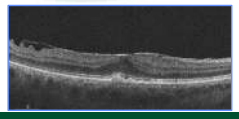

61

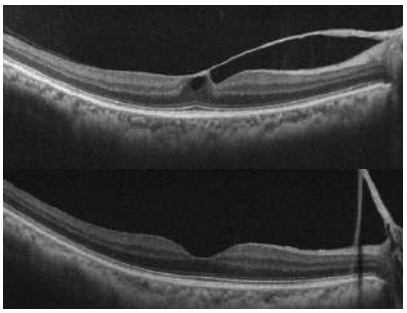

20/25-2

3 [illegible]

20/20-2

62

Is it Full Thickness?

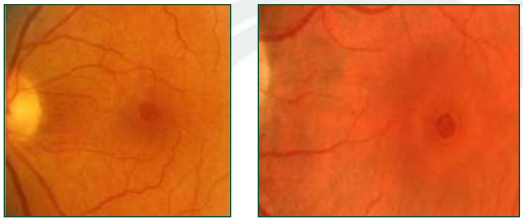

Pseudoholes vs. Full Thickness Holes

63

Is it Full Thickness?

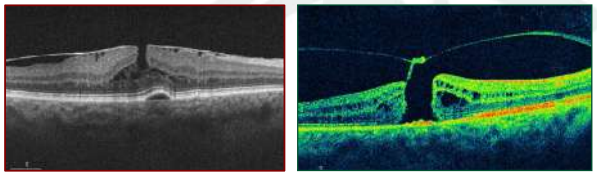

64

Myopic Macular Retinoschisis

- Seen in 9% of highly myopic eyes with posterior staphyloma
- 50% progress to macular hole formation or macular detachment within 2 years
- **Caused by rigidity of ILM that induces traction**

65

Jeff: mid-50's Attorney, High Myopia

Hx of RD Repair in both eyes: RE: 1985 LE 1989

- Never recovers vision in the RE
- He is followed through the 90's with a progressive NS and declining Va ~ 20/70
  - 1 eyed patient and reluctant to have CE
- Eventually has CE/IOL 90's-early 2000's and does well
  - VA 20/25 low refractive error

66

11/22/13
20/30

67

11/22/13

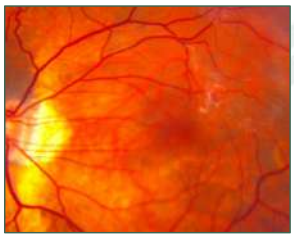

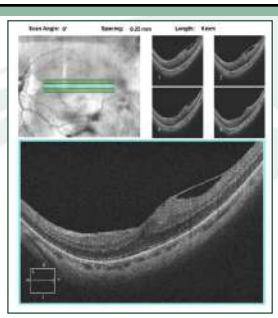

68

2015 20/30

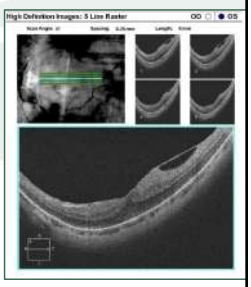

69

Jeff: High Myopia and VMT

3/11/19

- Feels Vision is slightly worse, increase in distortion

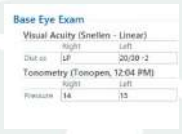

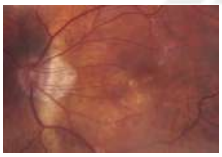

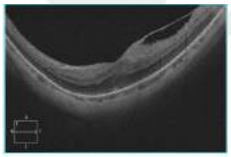

70

3/11/2019

Progress Notes

Impression
1) ERM LE - stable from 2015
   Repeat OCT and fundus photos - stable
2) History of RD OU repair by Dr. Clarkson (1985, 1989) with good result
3) Had poor vision RE due to ERM and now dense cataract -> LP vision
4) Pseudophakia LE (~ 10 yrs ago)

Plan
1) Ed and reassure
2) Rx given for specs
3) RTC 1 yr
4) Seen with Dr. Jay Shridhar

71

The OCT in Glaucoma

72

The OCT in Glaucoma

- When is it glaucoma?
  - Differentiating glaucoma nerves from physiologic nerves
  - Sometime it's very easy but not always
- Following glaucoma suspects
  - Recognizing early change -> **green disease**
  - Recognizing when it's NOT glaucoma – **red disease**
- Determinging progression
- When is the OCT not as helpful?

73



74



75



76

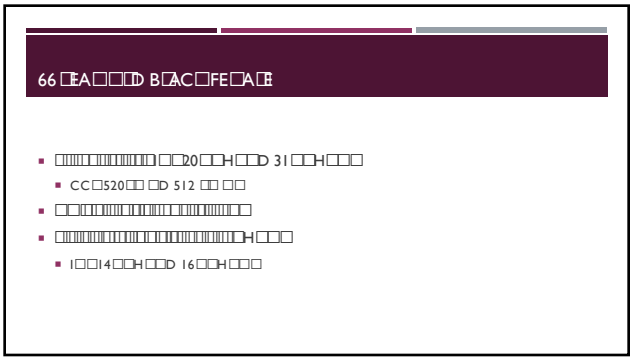

77

Do you only do 1 RNFL scan?

- How do you know how accurate/reliable that scan is?
- Instead do 3 RNFL scans at a time
  - at a minimum do 2 scans
- Ensures consistency/reliability

78

Frequency of Optical Coherence Tomography Testing to Detect Progression in Glaucoma

Bruna Melchior, MD,*† Carlos G. De Moraes, MD, PhD, MPH,* Jayter S. Paula, MD, PhD,† George A. Cioffi, MD,* Christopher A. Girkin, MD, MSPH,‡ Massimo A. Fazio, PhD,‡ Robert N. Weinreb, MD,§ Linda M. Zangwill, PhD,§ and Jeffrey M. Liebmann, MD*

(J Glaucoma 2022;31:854–859)

79

What is the Reproducibility of RNFL OCT Clock Hour Measurements

A. 0-3 microns
B. About 4-5 microns
C. About 10 microns
D. > 10 microns

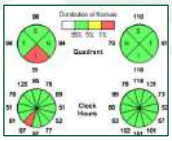

80

RNFL Quadrants and Clock Hours

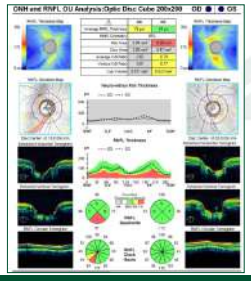

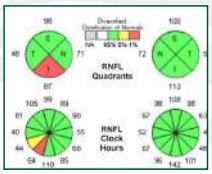

Inter-visit Tolerance:
Clock Hours: ~ 4-5 microns
Quadrant: 8-10 microns

81

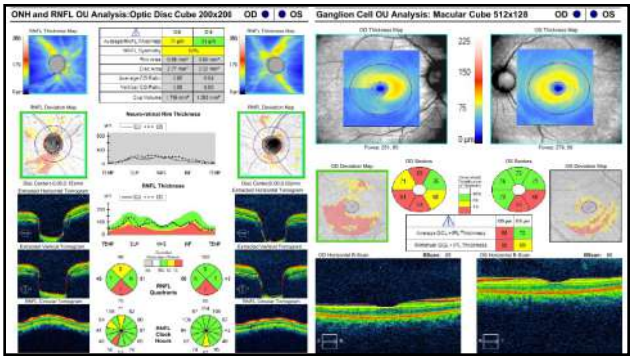

82

How much change needs to occur on an OCT RNFL for it to be significant?

83

How much change needs to occur on an OCT RNFL for it to be significant?

- 5 microns
- **10 microns**
- 20 microns
- 25 microns

84

49 [illegible]B[illegible]

[illegible]25[illegible]H[illegible]
[illegible]D 23[illegible]H[illegible]

CC[illegible]559μ[illegible] [illegible]D 561μ[illegible] [illegible]

[illegible]H[illegible], [illegible]0.5% BID [illegible]

I[illegible]20[illegible]H[illegible]D 17[illegible]H[illegible]

85

Can the RNFL/optic nerve of your patient be applied to the normative data base?

- Pathologic myopia
- Tilted disc
- Extremely large cups (and small)
- Patients less then 18 yo

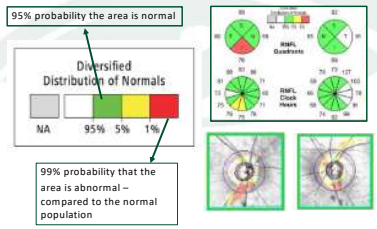

86

D[illegible]?

G[illegible]

H[illegible]

H[illegible]B30 [illegible]
218 [illegible]H[illegible]45 H[illegible]41 B[illegible]23 A[illegible]3 A[illegible]
I[illegible]
A[illegible]18-78
[illegible]C[illegible]282 [illegible]
A[illegible]19-84; 6 [illegible]I [illegible]C[illegible]
133 [illegible]149 [illegible]43% C[illegible]24% A[illegible]18% A[illegible]A[illegible]12% H[illegible]1% I[illegible] 6% [illegible]
[illegible]600 [illegible]
19-84 [illegible]11 [illegible]A, [illegible]I[illegible]E[illegible]

G[illegible]= 95% [illegible]
[illegible]= <5%
[illegible]= <1%

87

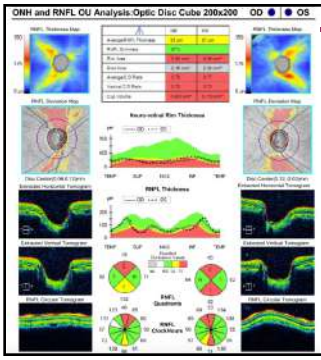

I[illegible]

H[illegible]

88

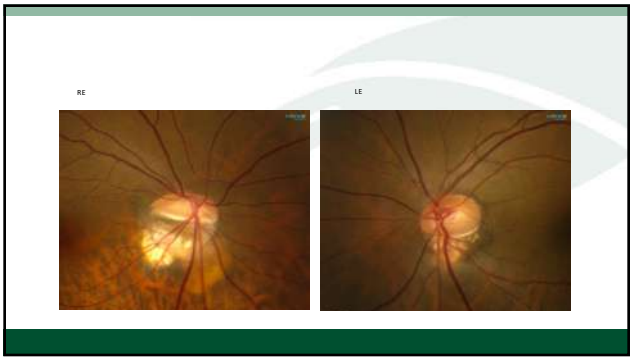

89

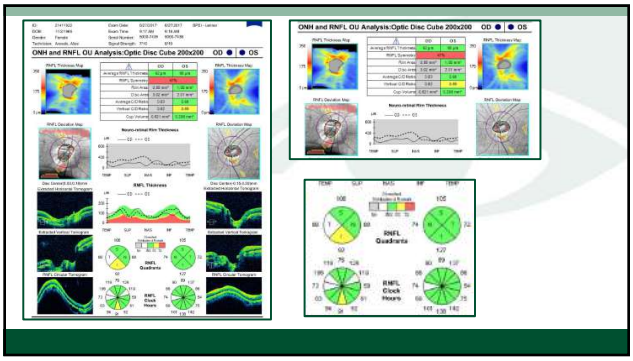

90

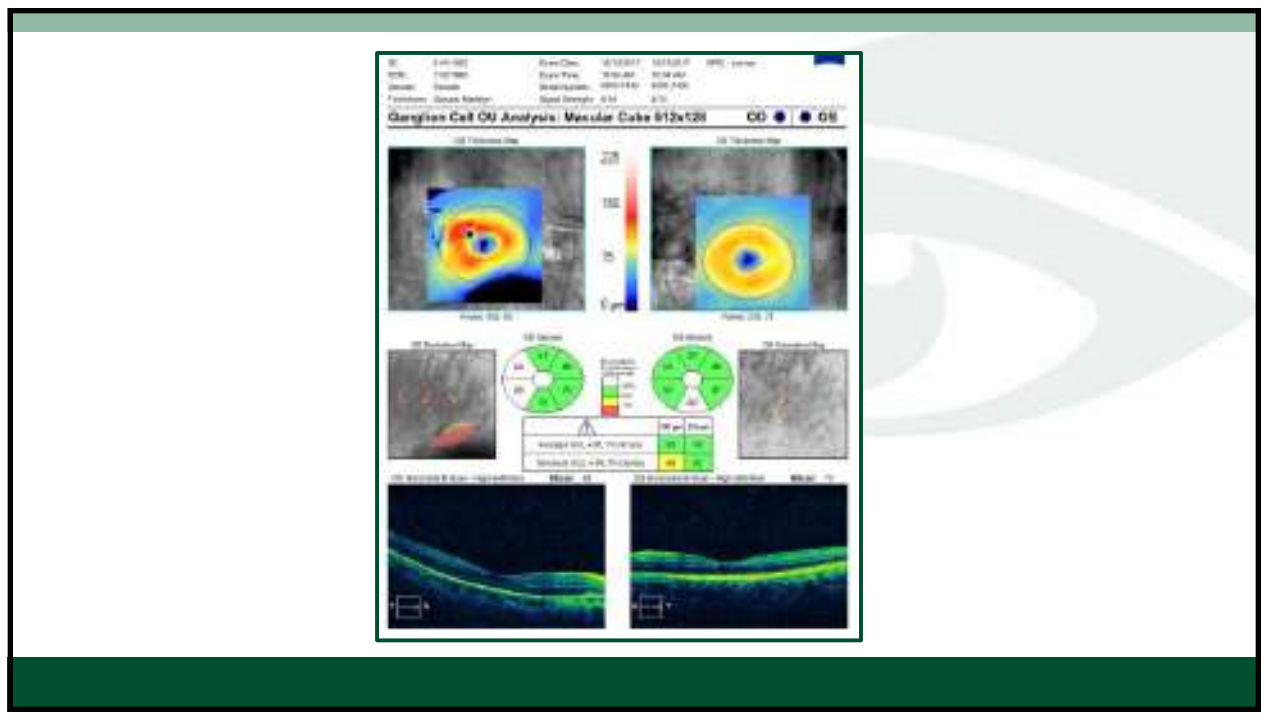

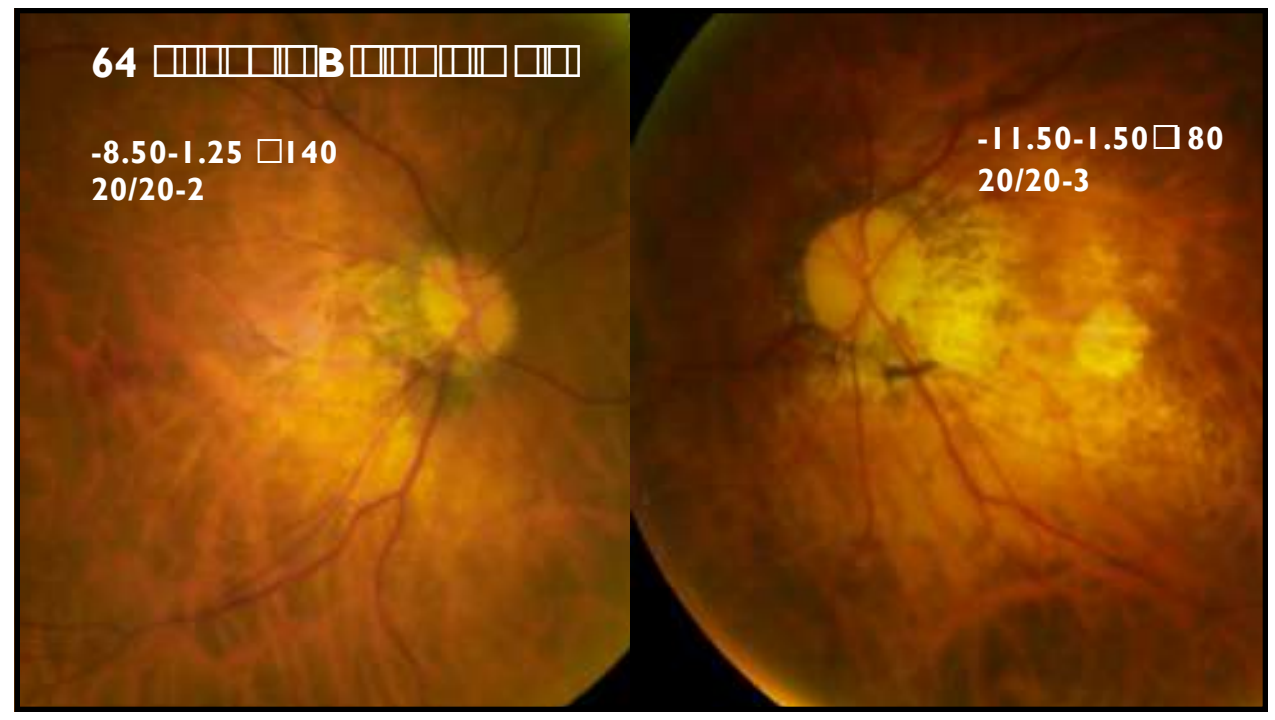

64 year old **B**lack female

-8.50-1.25 X 140
20/20-2

-11.50-1.50X 80
20/20-3

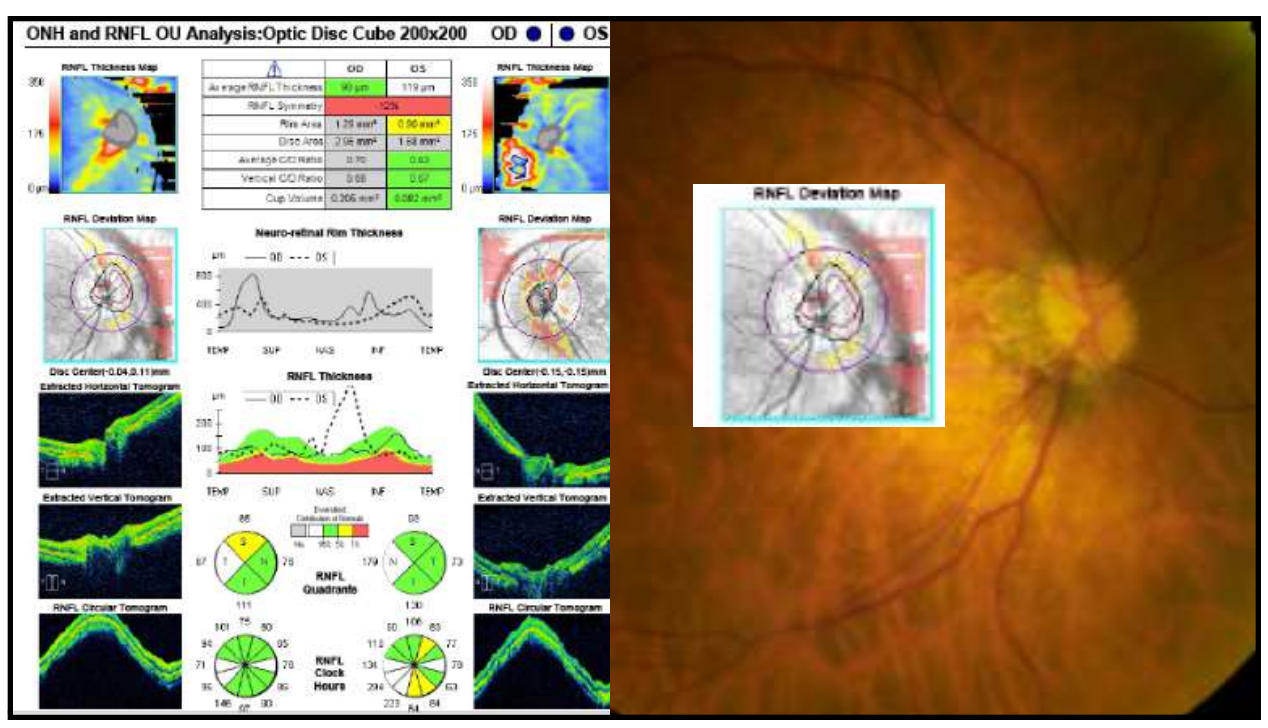

OCT Evaluation of the Anterior Chamber

No inadvertent compression

May be performed in complete darkness

Most valuable to determine if the angle is open or closed

41 □EA□□□D FE□A□E

- Pinhole A 20/20 □D and OS
- IOP 18/19mmHg
- Gonioscopy
  - □D: No structures seen superior and temporal anterior trabecular meshwork nasal and inferior
  - OS Anterior trabecular meshwork 360
  - Convex iris approach no PAS NVI, A□360 OD and OS (with compression)

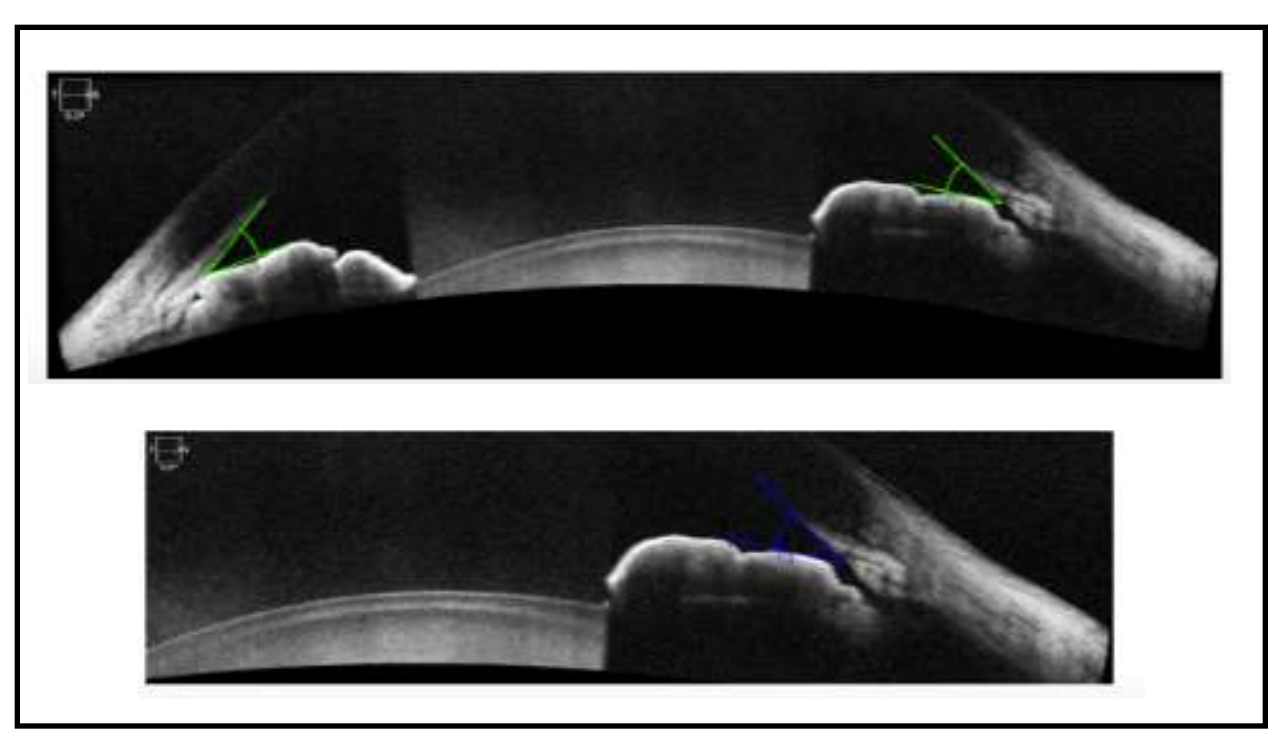

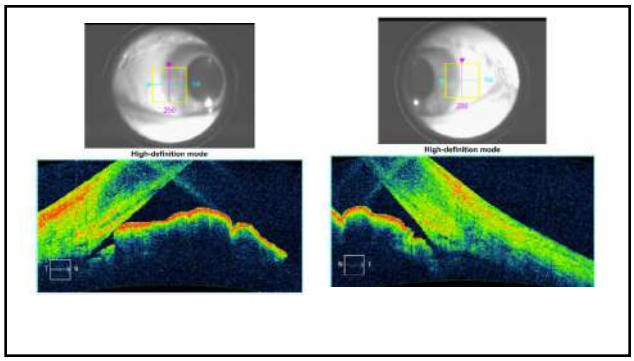

97

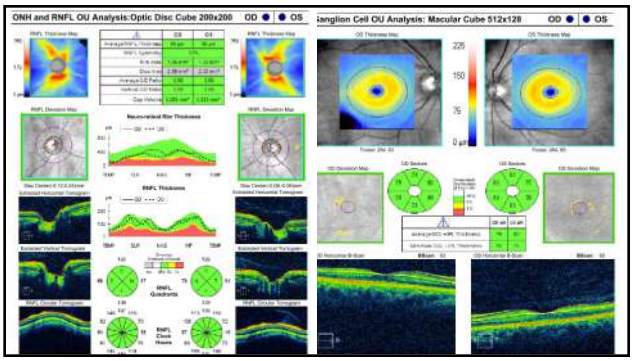

98

When is it glaucoma?

99

72 y/o White Male

- Routine eye exam
  - VA OD – 20/30, OS – 20/30-2
  - 1+ NS OU, 1+ PSC OU
  - IOP – **OD 32mm Hg, OS 34mm Hg**
  - C/D - OD .6/.6, OS .75/.75 (thin beta zone temporally)
  - Pachymetry – OD 543, OS 534

100

72 y/o White Male

101

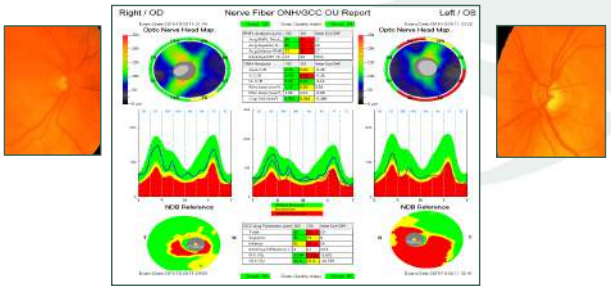

102

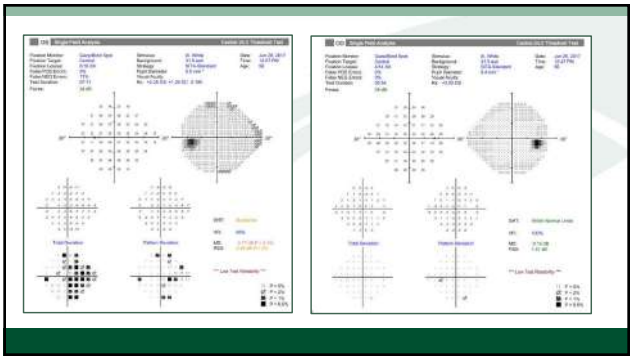

103

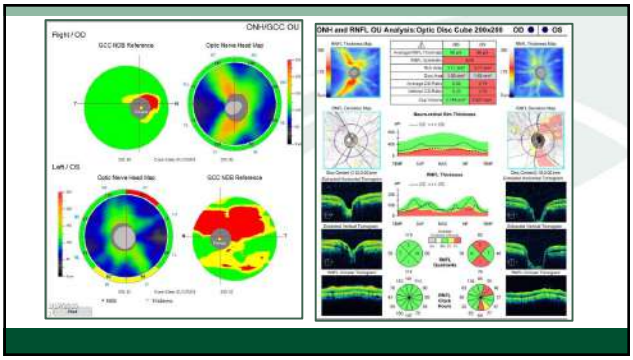

104

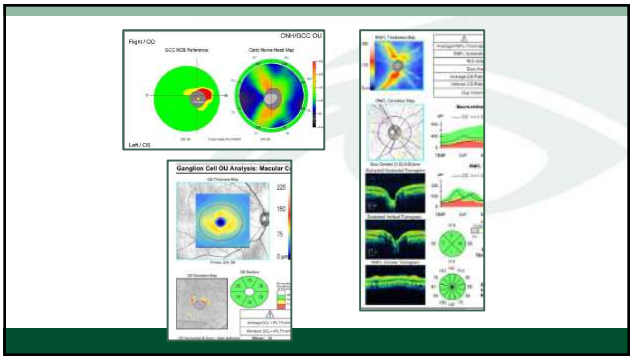

105

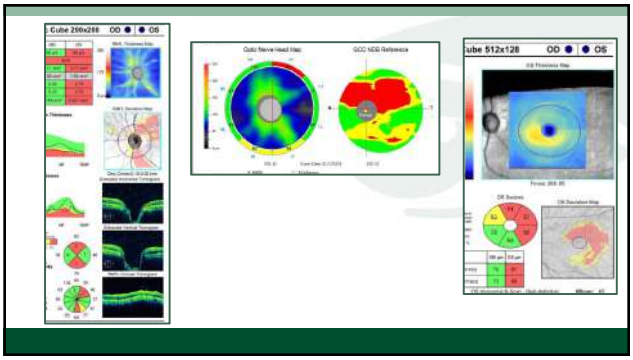

106

When is it Glaucoma?

There is a large range of ”normal” before the RNFL reaches the “tipping point”

Be on the lookout for **Green Disease!!**

107

The Anatomy of the RNFL Printout

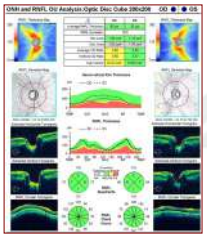

	OD	OS
Average RNFL Thickness	93 µm	91 µm
RNFL Symmetry	92%	
Rim Area	1.00 mm²	1.10 mm²
Disc Area	1.52 mm²	1.37 mm²
Average C/D Ratio	0.60	0.45
Vertical C/D Ratio	0.60	0.47
Cup Volume	0.223 mm³	0.093 mm³

Average RNFL Thickness Ranges ~ 75 -110 microns

Tipping Point = 75 microns

108

There is a Large "Range" of Normal

- *Just like perimetry, the average patient can lose a third of his/her RNFL or neuro-retinal rim and still be inside the normal range.*

Average RNFL Thickness
75 microns – tipping point

Floor Affect in Advanced Glaucoma
40-50 microns

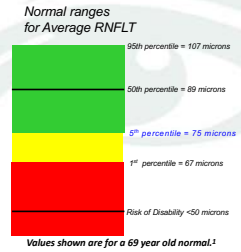

Values shown are for a 69 year old normal.[1]

109

What This Means For Everyday Clinical Care

- We can measure multiple steps of statistically significant change while a glaucoma suspect still is in the green normal range
- It is possible to view SDOCT change from baseline as an early detection strategy in glaucoma suspects.

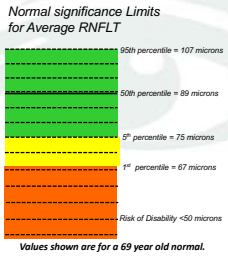

Values shown are for a 69 year old normal.

110

Large Range of Normal Before Tipping Point

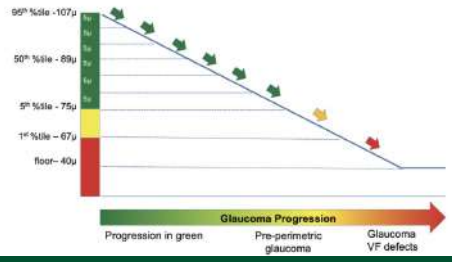

Glaucoma Today: March/April 2021; Patella M, Goni F, Bron A, Heijl H. Aurora Meeting; 2015; Berlin, Germany.

111

The OCT can show glaucomatous change
BEFORE it is seen on visual fields

In fact – may be MORE sensitive than visual fields in detecting progression

112

Estimating the Lead Time Gained by Optical Coherence Tomography in Detecting Glaucoma before Development of Visual Field Defects

Tanmy M. Kwong, MD,[1,2] Chunsei Zhang, MD,[1,3] Linda M. Zangwill, PhD,[1] Robert N. Weinreb, MD,[1] Felipe A. Medeiros, MD, PhD[1]

Ophthalmology. 2015 Oct;122(10):2002-9.

- At 95% specificity, up to **35% of eyes had abnormal average RNFL thickness** 4 years before development of visual field loss and **19% of eyes had abnormal results 8 years before field loss.**
- **Conclusions:** Assessment of RNFL thickness with OCT was able to detect glaucomatous damage before the appearance of VF defects on SAP. In many subjects, significantly large lead times were seen when applying OCT as an ancillary diagnostic tool.

113

114

OCT Detects Progression Before VF

- OCT can detect progression 1-2 years before it shows up on VF
- **Both NFL and GCC outperform** VF in detecting progression in early glaucoma
- In moderate and advanced GL, RNFL looses sensitivity due to floor effect
- GCC continues to detect progression in moderate and advance glaucoma

115

Detecting Glaucoma Progression Using OCT - RNFL

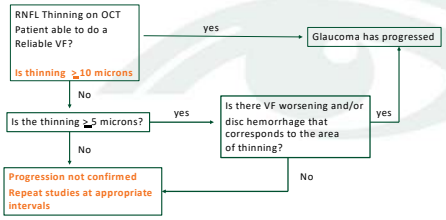

116

When is it glaucoma?

Red Disease

Abnormal OCT findings in the absence of glaucoma

117

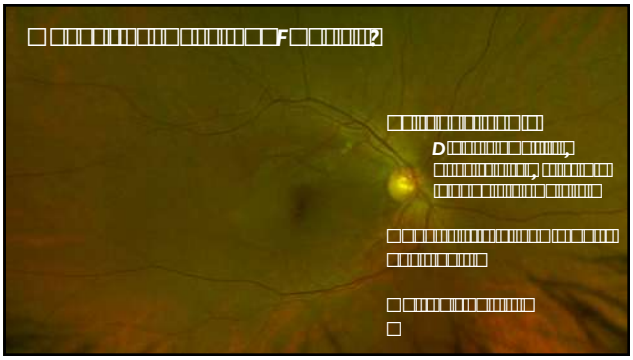

118

When the OCT is not helpful

119

When the OCT is not helpful

Severe glaucoma
- Floor Affect in Advanced Glaucoma ~40-50 microns
- Difficult to use the OCT to measure progression

High Myopia
Tilted Discs

120

Summary OCT in Glaucoma

- OCT provides another piece information for the **"glaucoma puzzle"**
  - Along with IOP, visual fields and clinical appearance of the nerve
- It provides an objective means of comparing "glaucomatous" nerves from normal or physiologic optic nerve
- It provides an objectives means of determining progression

121

Summary: OCT in Retina

- SD OCT has emerged as a critical tool in the diagnosis and treatment of retinal disease
- It has changed how we evaluate the macula
- Helps establish a diagnosis that is difficult to determine with only standard ophthalmoscopy
- Advancing software has provided expanded uses OCT
- OCT Angiography has taken OCT to the next level

122