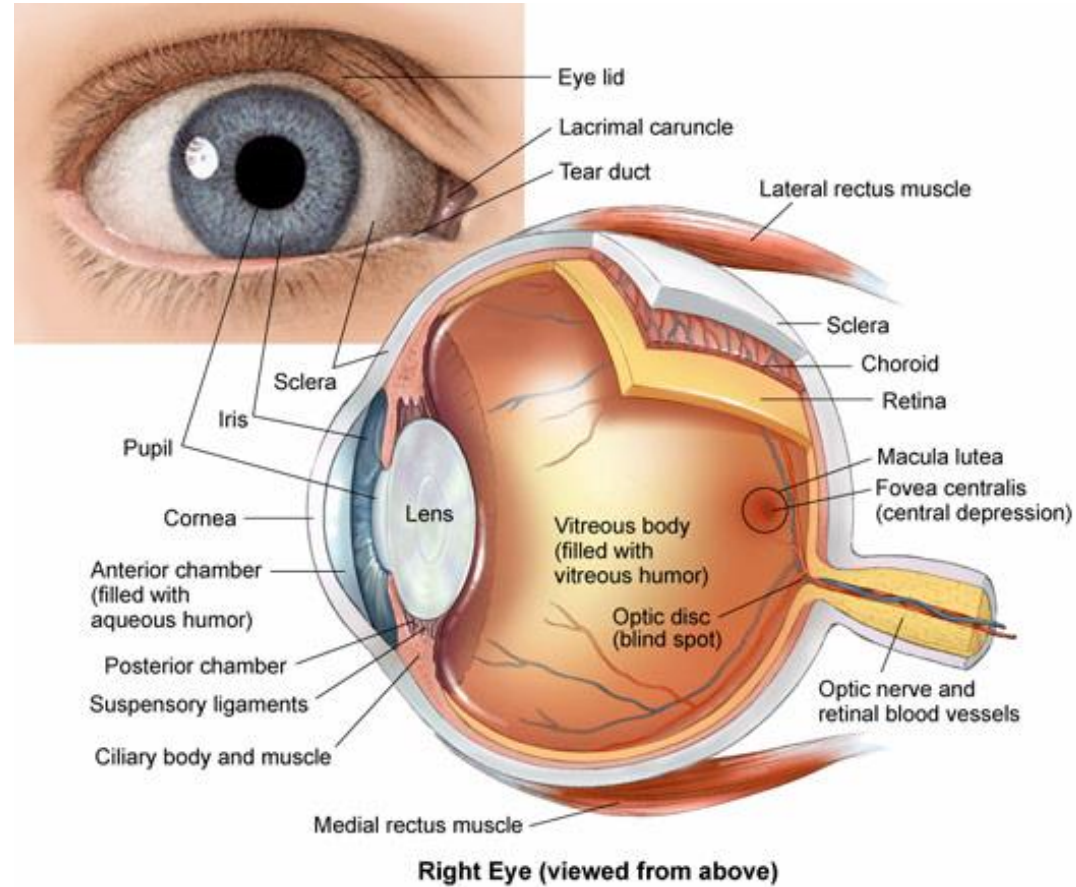


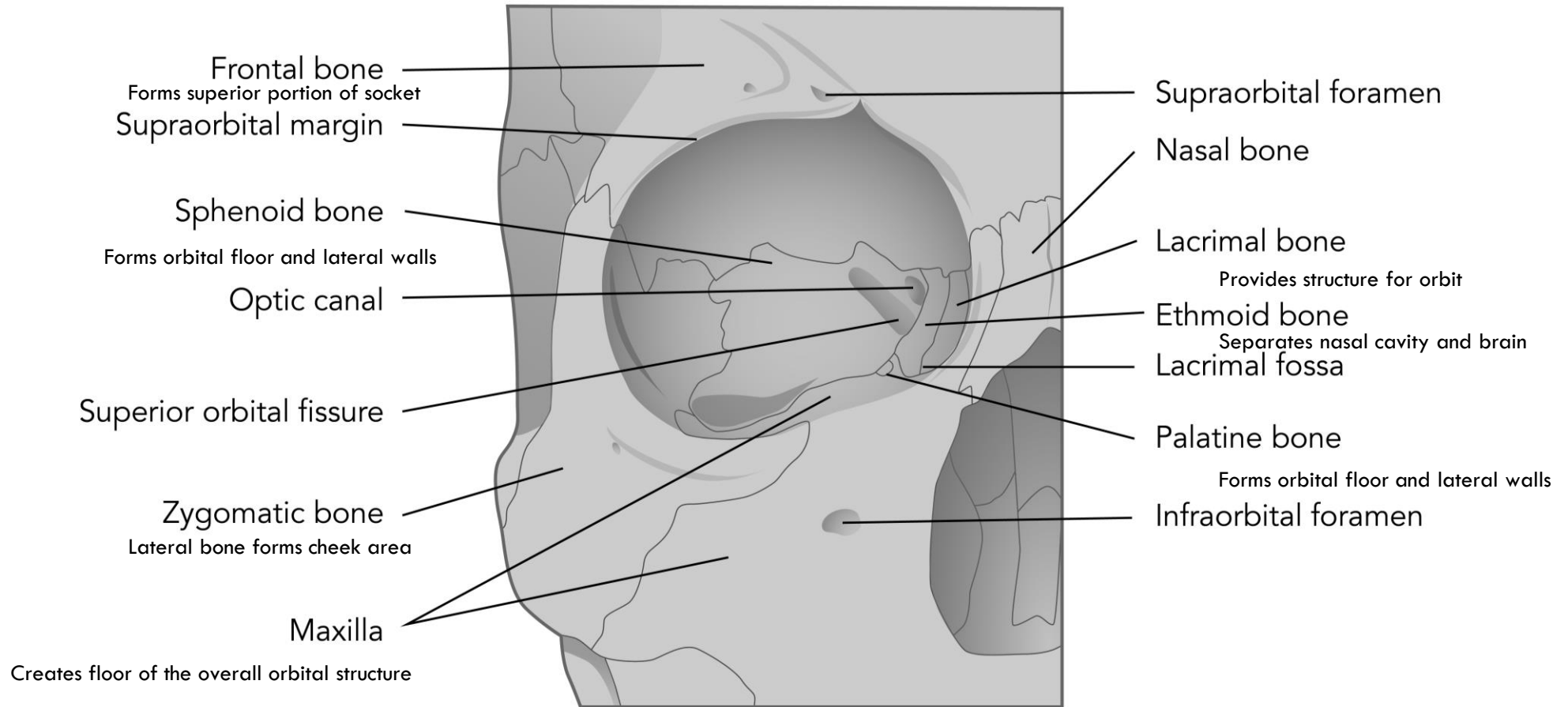
Ocular Anatomy and Physiology for Opticians

—
Carri Rivera FCLSA, NCLEM

Ocular Anatomical Structures



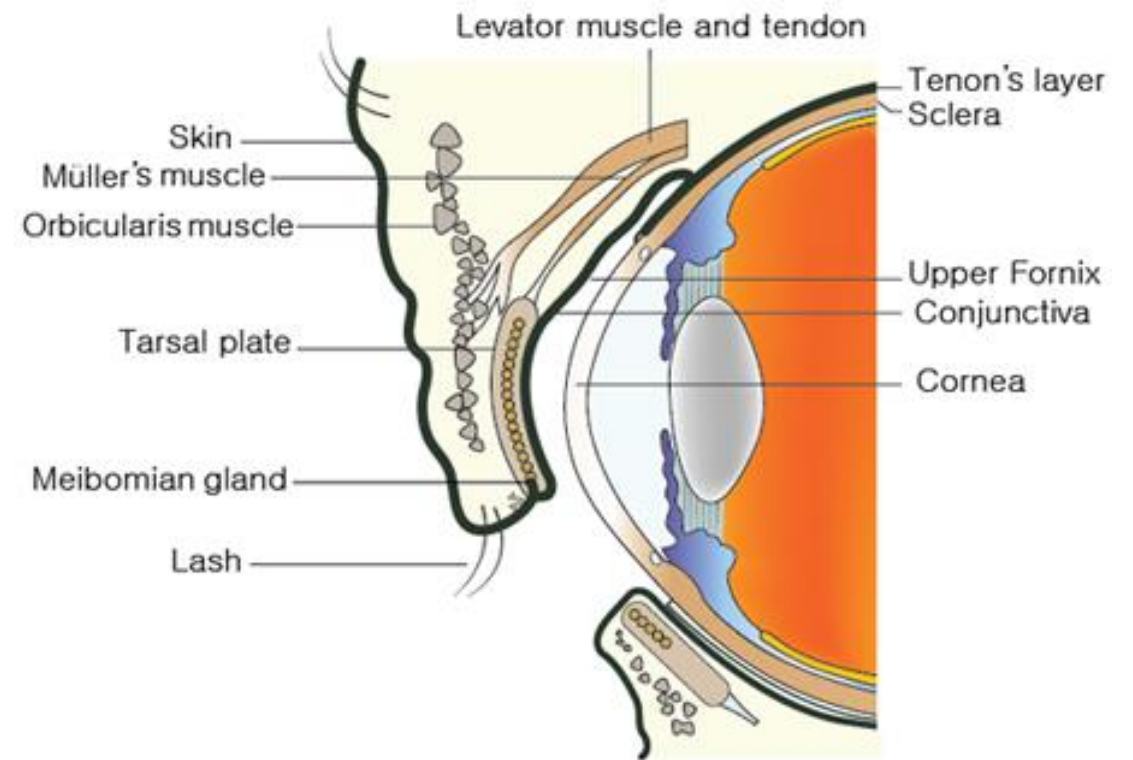
Orbital Bones



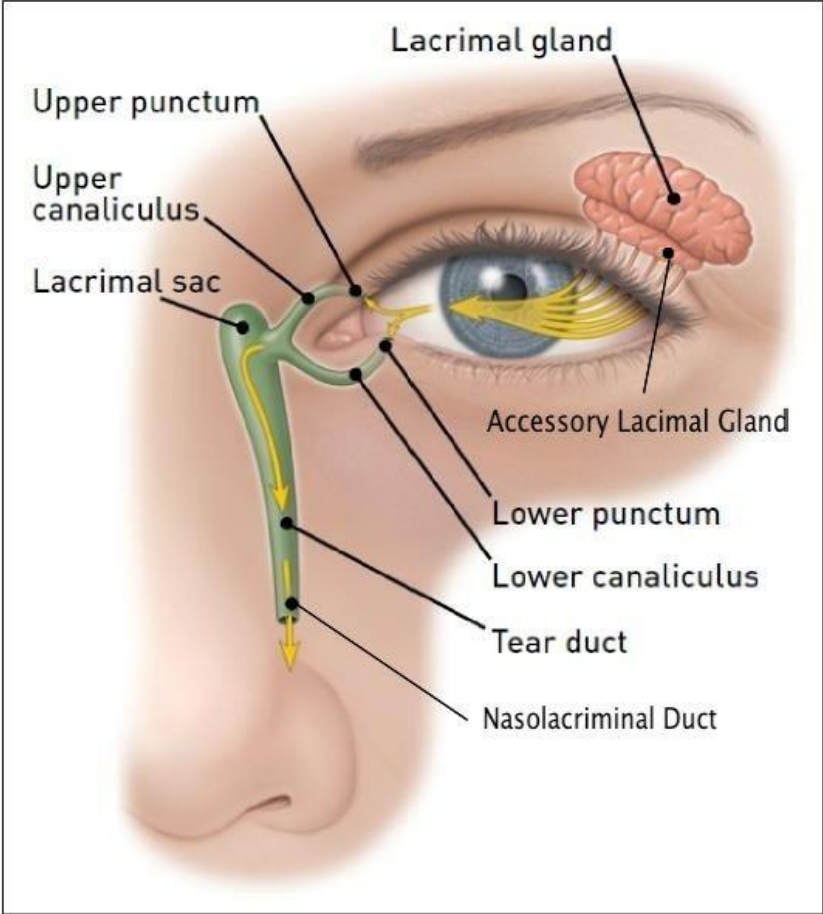
Eyelids

Function:

- Protects the globe
- Provides a sufficient aperture for vision
- Prevents drying of the eyes
- Aids in normal tear film and drainage
- Secretes the oily part of the tear film



Lacrimal Gland System



Tear Film

95% of the volume is produced by the lacrimal gland

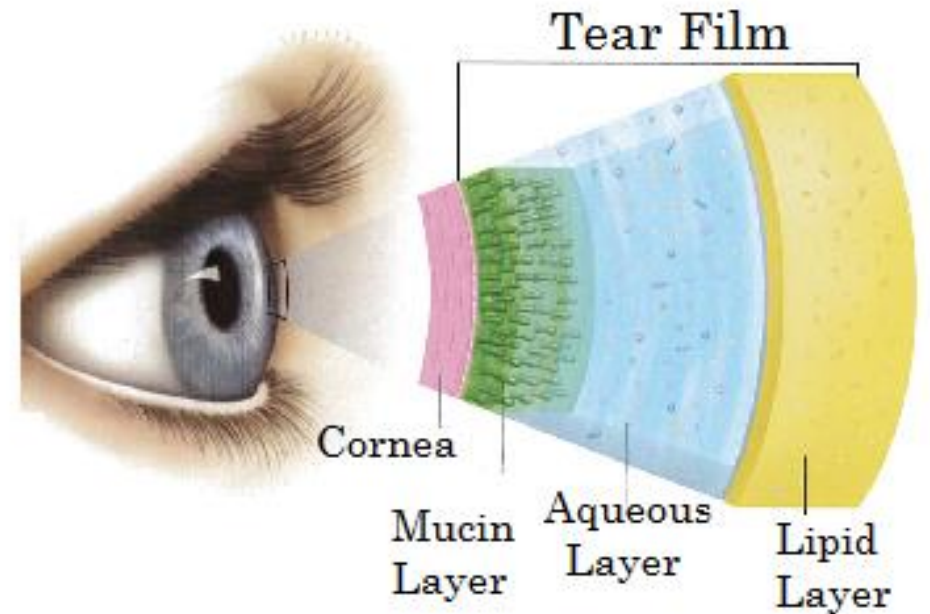
Glands and cells of the lids and conjunctiva produce the remaining 5%

50% of the tear is located along the lid margin known as the tear meniscus or lacrimal lake

The remaining 50% of the tear is spread over the cornea and anterior surface

Has 3 layers

- Lipid
- Aqueous/Water
- Mucin



Tear Film Function

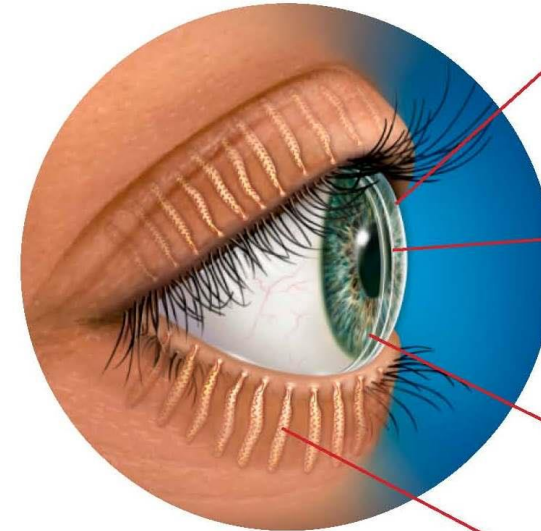
In contact lens wear, the tear film provides a smooth optical surface for the contact lens

Lubricates the ocular surface

Provides antimicrobial function

Helps to remove bacteria and denatured epithelial cells

Acts as a vehicle for the diffusion of oxygen and nutrients



Lipid (oil) layer:
lubricates and prevents evaporation

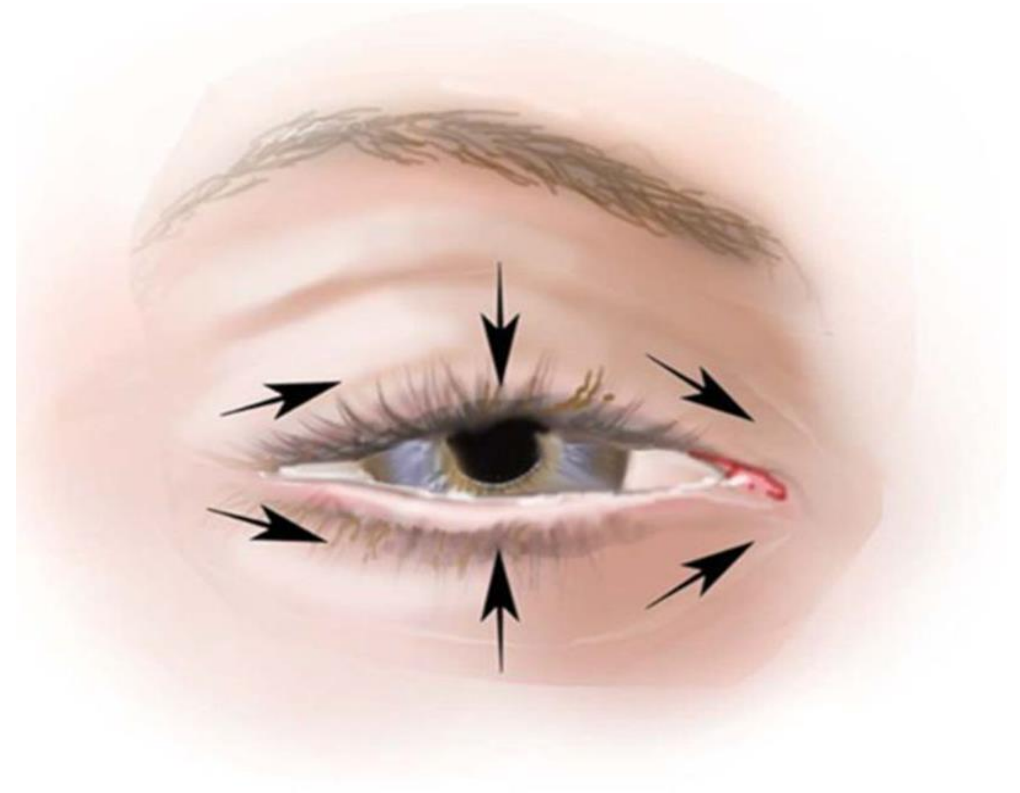
Aqueous (water) layer:
nourishes and protects the cornea

Mucin layer:
adheres tears to the eye

Meibomian glands:
create the lipid (oil) layer of the tear film

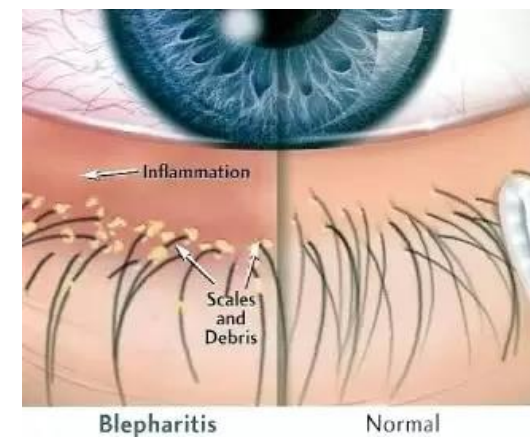
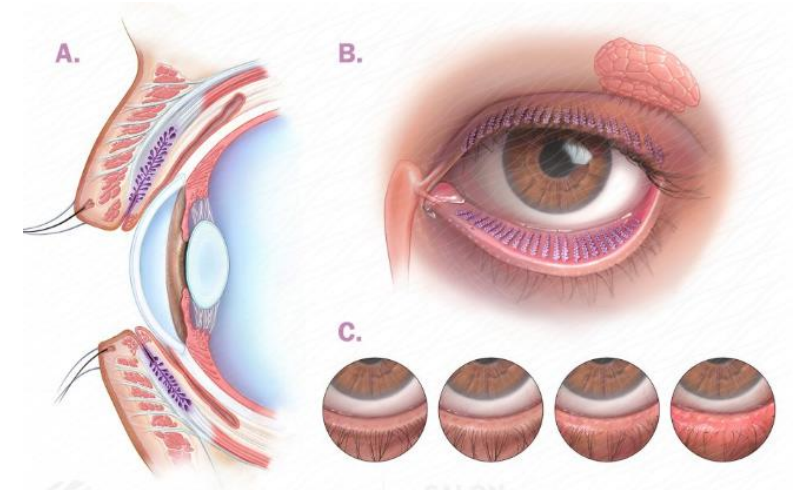
Blinking Mechanism

- Orbicularis oculi muscle is responsible for blinking
- Levator palpebrae superioris muscle keeps the lid open
- Interpalpebral fissure - widest opening (approximately 10mm vertically and 30mm horizontally) between the upper and lower palpebrae



Meibomian Glands

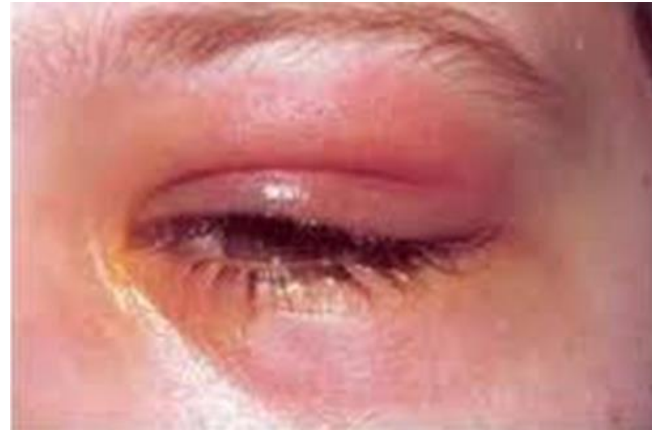- **Meibomian glands** (also called tarsal glands) are located along the rims of the eyelid in the tarsal plate (25 upper and 20 on lower lids)
- Produce meibum, an oily substance that prevents evaporation of the tear film
- Meibum prevents tears from spilling onto the cheek, traps them between the oiled edge and the eyeball, and makes the closed lids airtight



Lacrimal system disorders

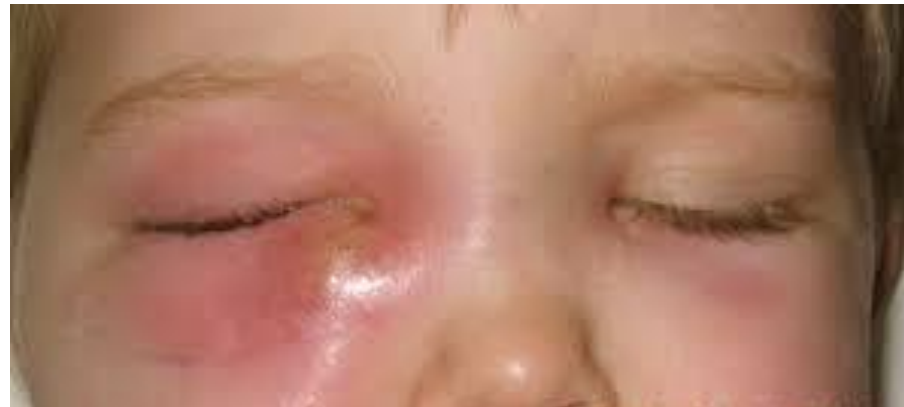Dacryoadenitis

- inflammation of the lacrimal gland
- Rapid onset
- Unilateral; severe pain



Dacryocystitis

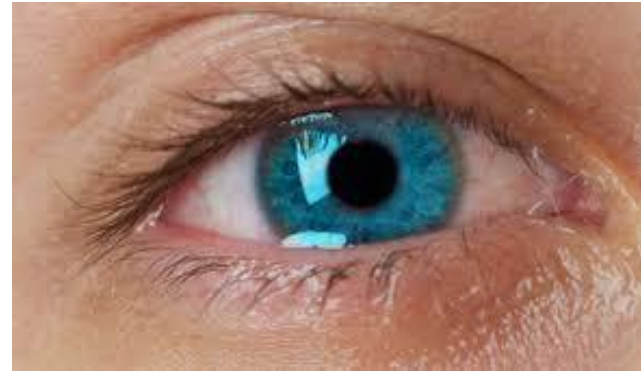- inflammation of the lacrimal sac
- Rapid onset
- Unilateral; severe pain; epiphora



Lacrimal system disorders

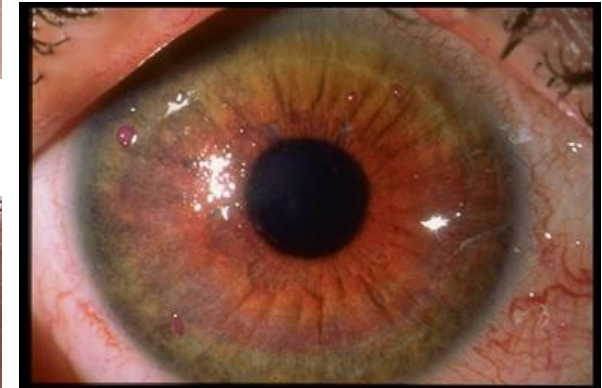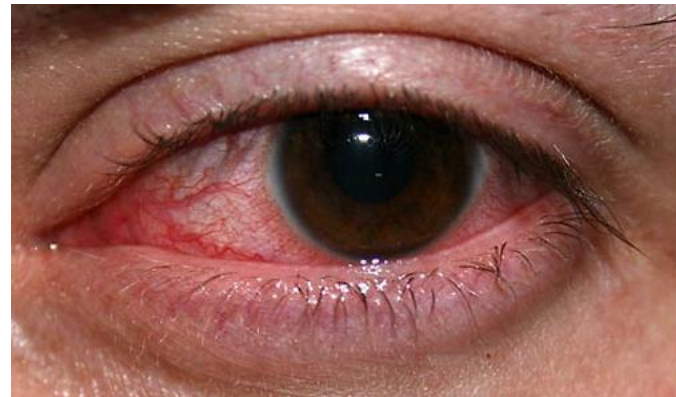
Epiphora

- tears spilling onto cheeks due to faulty drainage



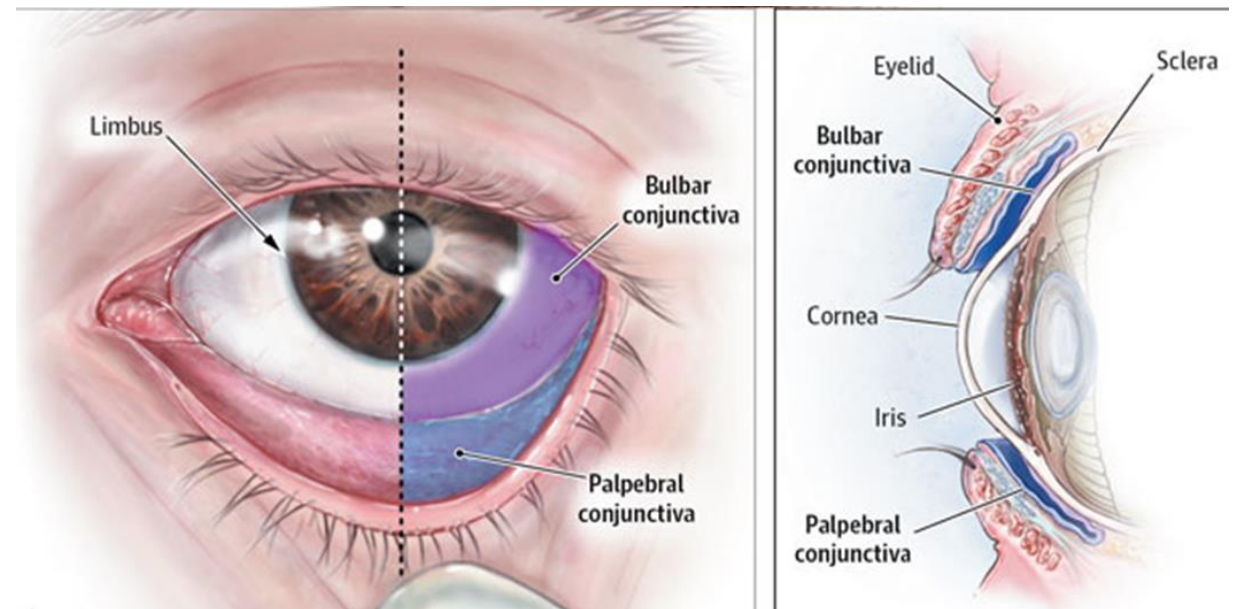
Keratitis sicca

- inflammation of the cornea due to dryness associated with a tear deficiency



Conjunctiva

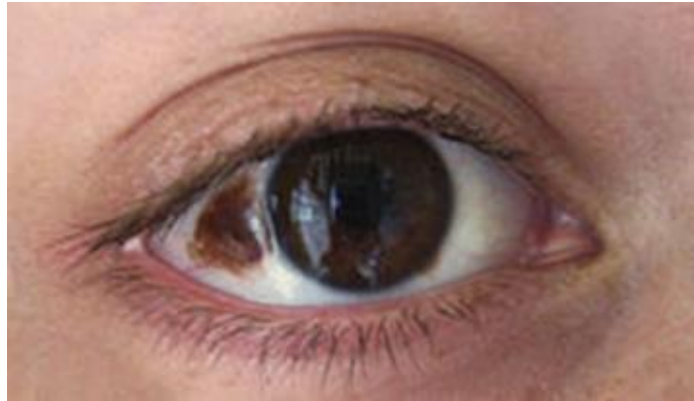- **Palpebral Conjunctiva** is a mucous membrane extending from the lid margins over the sclera to the limbal margins
- **Bulbar Conjunctiva** – mucous membrane that covers the globe



Conjunctival Disorders

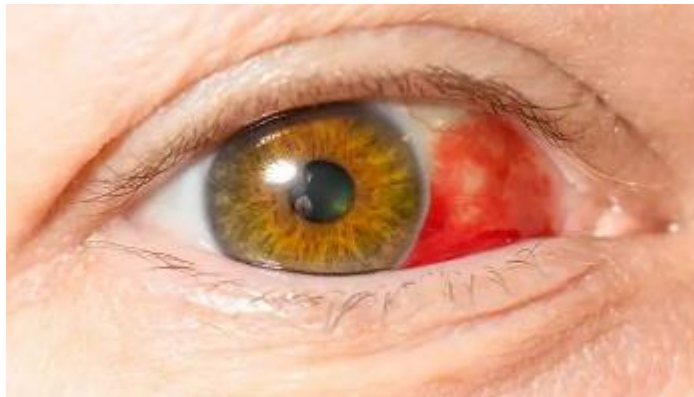Nevus

- small flat pigmented benign tumor



Subconjunctival hemorrhage

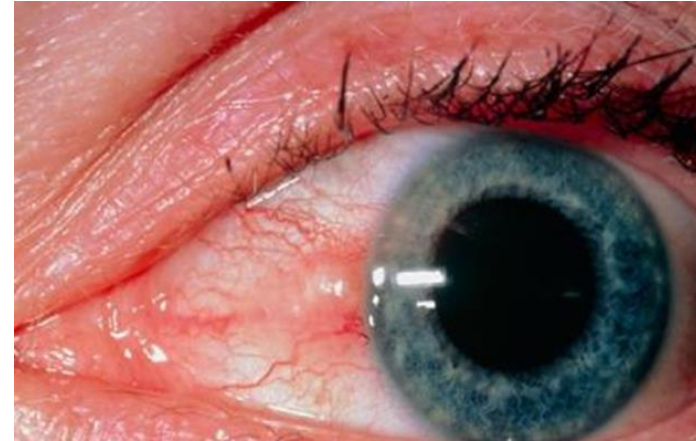
- blood from a broken vessel that is trapped under the conjunctiva



Conjunctival Disorders

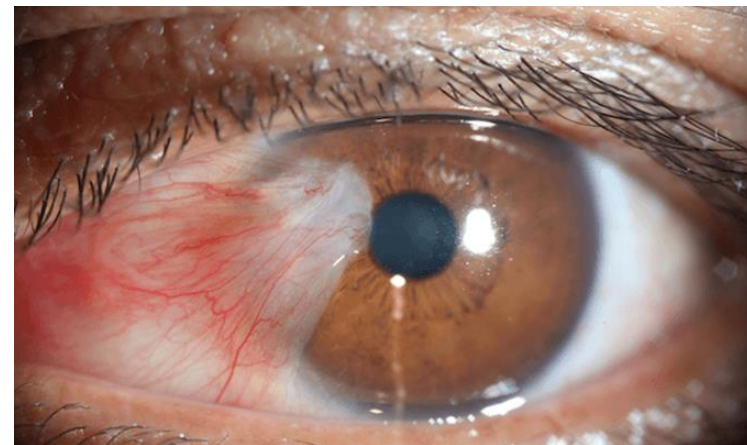
Pinguecula

- small rounded yellowish benign tumor



Pterygium

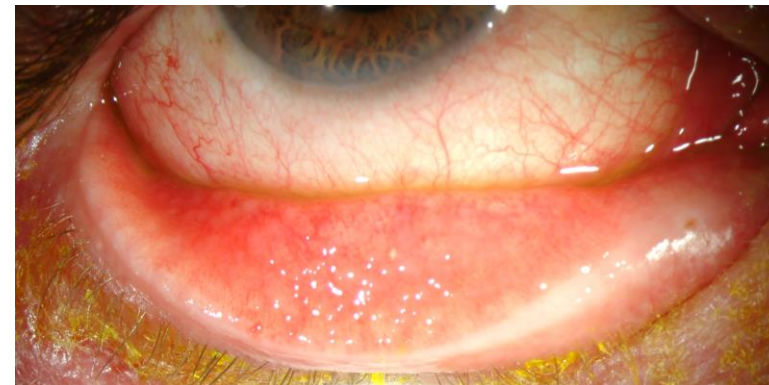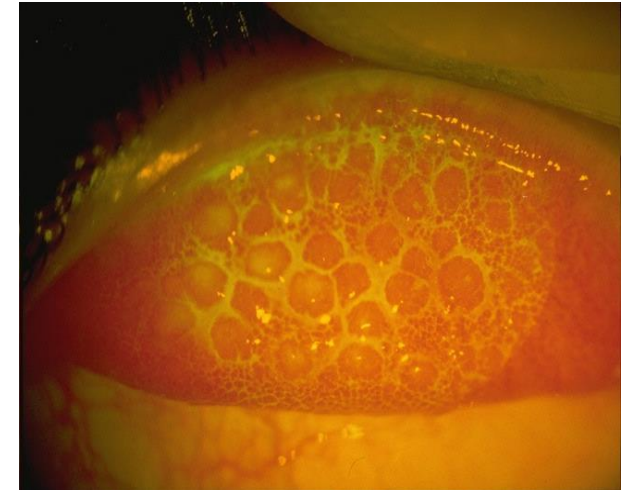
- wedge shaped overgrowth on the medial bulbar conjunctiva



Conjunctival Disorders

Superior and Inferior Tarsal Conjunctiva

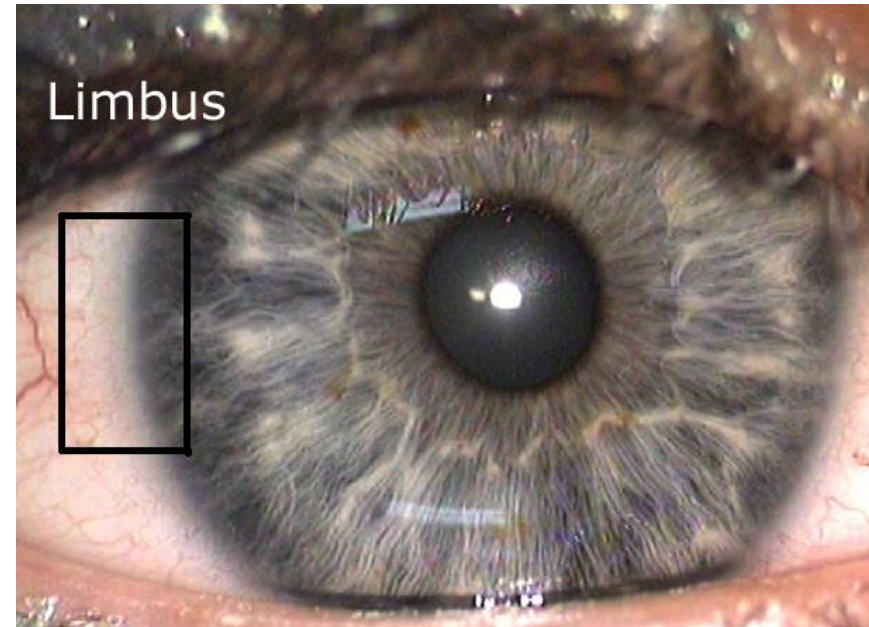
- Looking for papillae and Giant Papillary Conjunctivitis
- Contact lens problems with GPC?
 - The “jelly bumps” pull on the lens with each blink causing excessive lens movement which causes lens discomfort
 - Extreme ocular itching and secretion of mucous into tear film
 - To resolve requires antihistamine or steroid drops and holiday from contact lens wear



Limbus

Limbus

- The border of the cornea and the sclera
- 1.5mm to 2mm wide
- Provides outflow of aqueous humor
- Nourishes the peripheral cornea
- Assists in corneal epithelial regeneration



Cornea

Cornea is most powerful refracting surface of the eye

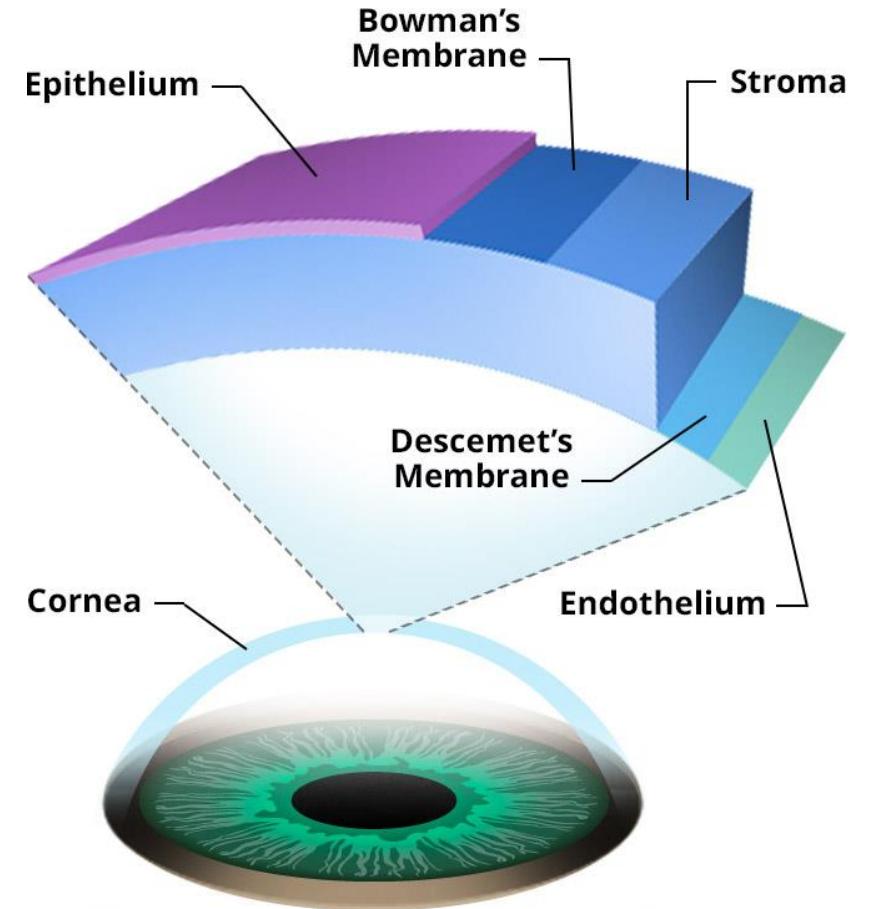
Clear window

No blood vessels

Accounts for approx. 2/3 of the eye's total optical power

5 layers

- Epithelium
- Bowman's Layer
- Stroma
- Descemet's Membrane
- Endothelium



Layers of the Cornea

Epithelium

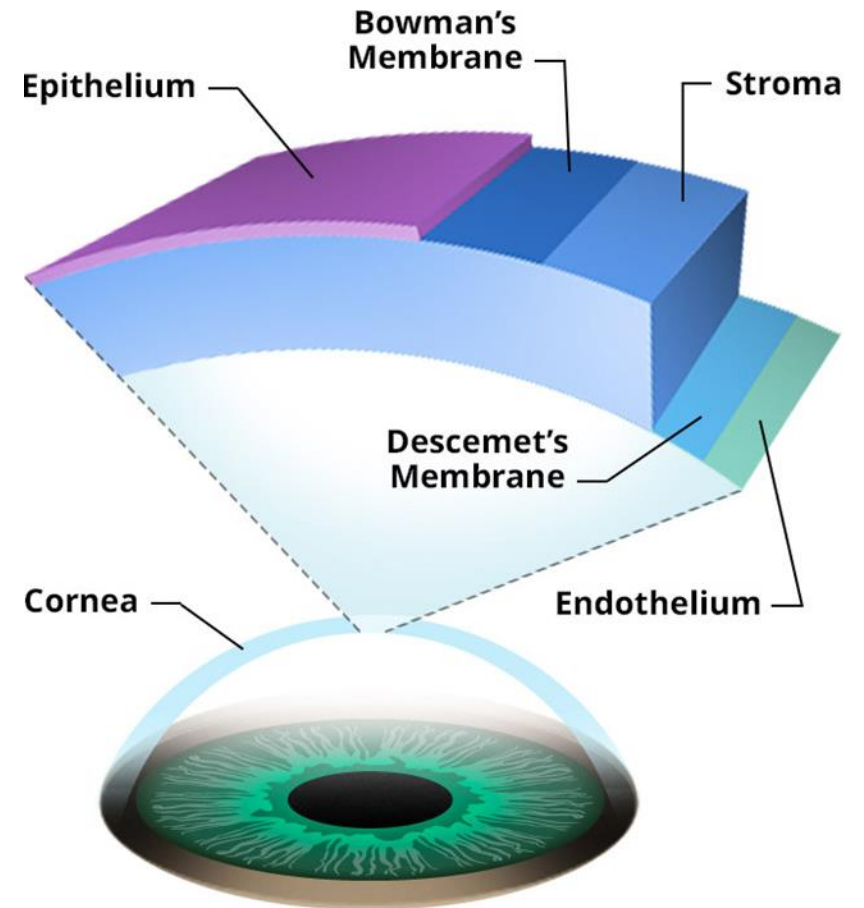
- The outer layer of cells act as a barrier against damage and infection
- Comprises about 10% of the total corneal thickness
- Regenerates every 7 days
- Provides a smooth surface that absorbs oxygen and cell nutrients from tears

Bowman's membrane

- A thin, tough membrane to help protect the cornea from penetration
- Cannot regenerate if damaged and therefore will scar

Stroma

- Accounts for 90% of the cornea's thickness
- Consists primarily of water (78%) and collagen fibers (16%)
- Collagen gives the cornea its strength, elasticity and form
- Cannot regenerate if damaged and therefore will scar



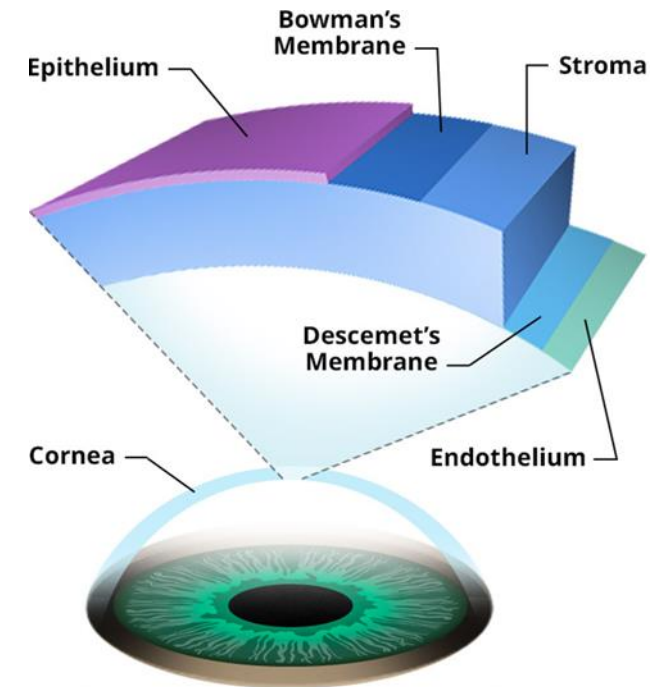
Layers of the Cornea

Descemet's membrane

- A thin membrane of collagen and elastic fiber
- Serves as a protective barrier against infection and injuries

Endothelium

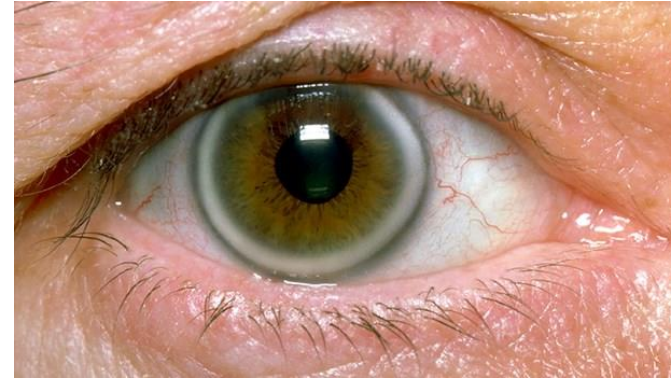- A layer of very delicate cells that are responsible for maintaining partial corneal dehydration and transparency
- This layer of cells pumps water from the cornea, keeping it clear.
- Without this pumping action, the stroma would swell with water, become hazy, and ultimately opaque.
- Cannot regenerate if damaged
- With normal aging, there is approximately 80% reserve of cells



Corneal disorders

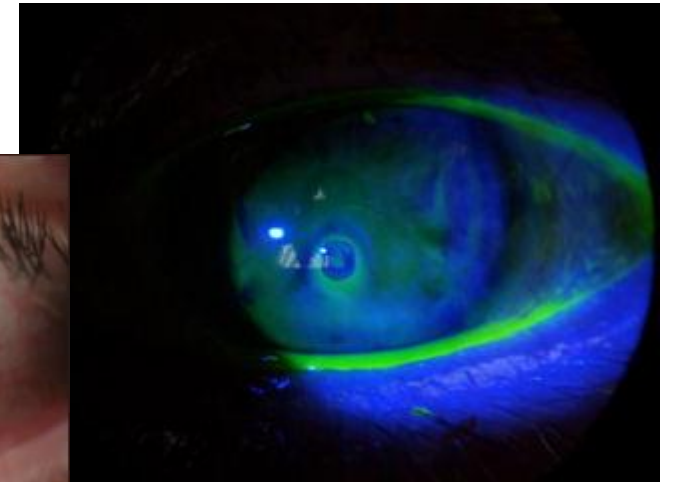
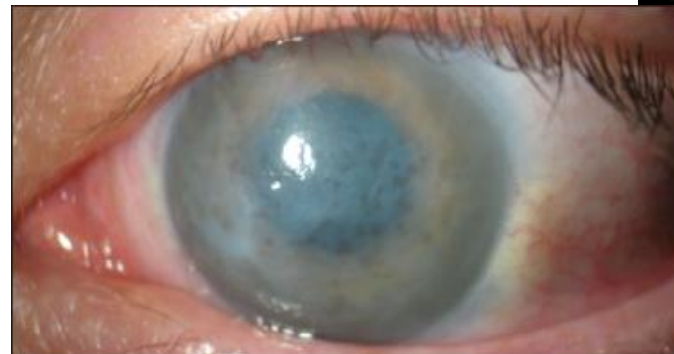
Arcus senilis

- Fat deposit that appears in the periphery of the cornea giving the appearance of a whitish ring around the outer edge. Most common in the elderly.



Bullous keratopathy

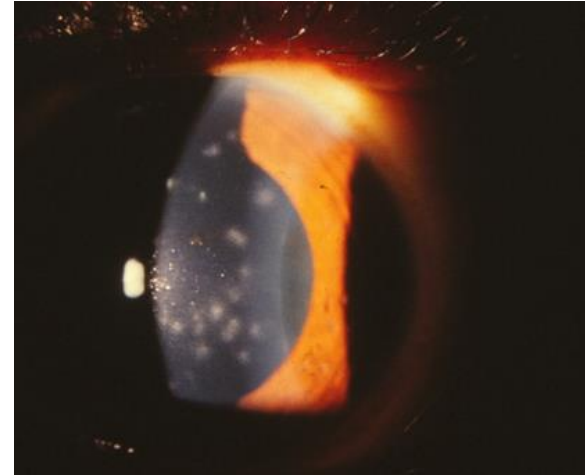
- Extensive swelling of the cornea caused by endothelial breakdown. Pockets of fluid, called the bullae form in the corneal tissue and rise to the epithelial surface where they break and cause pain



Corneal disorders

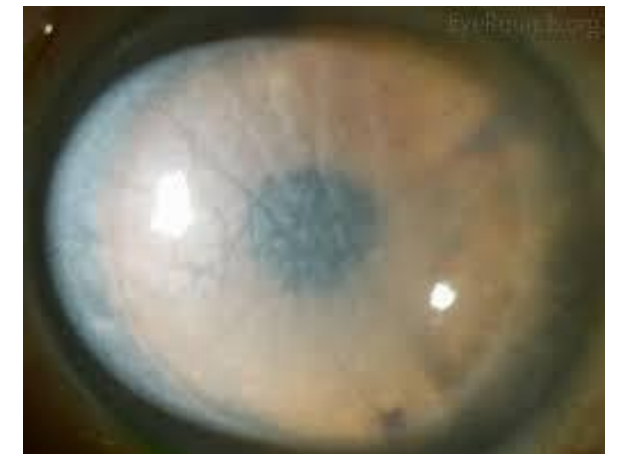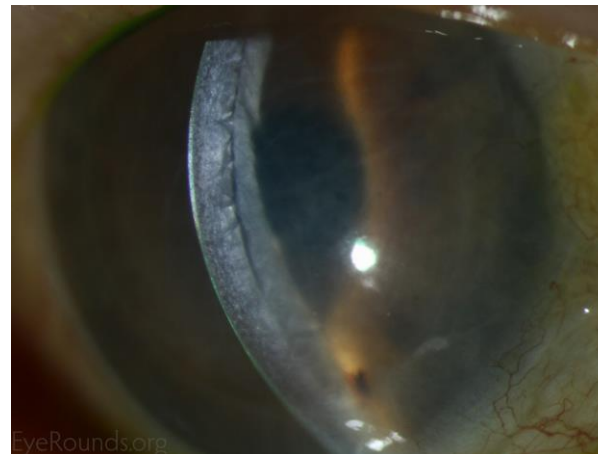
Infiltrates

- Groups of white blood cells in the corneal tissue



Edema

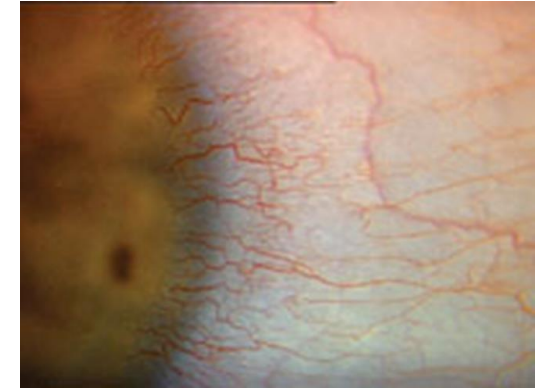
- Swelling or fluid retention of tissue



Corneal disorders

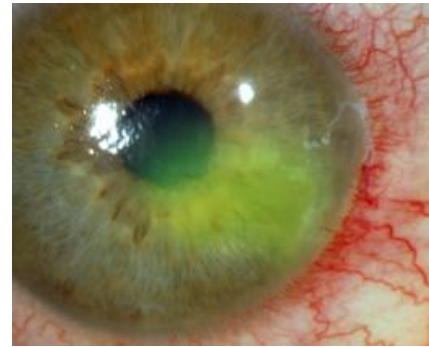
Neovascularization (corneal)

- new blood vessels in the cornea



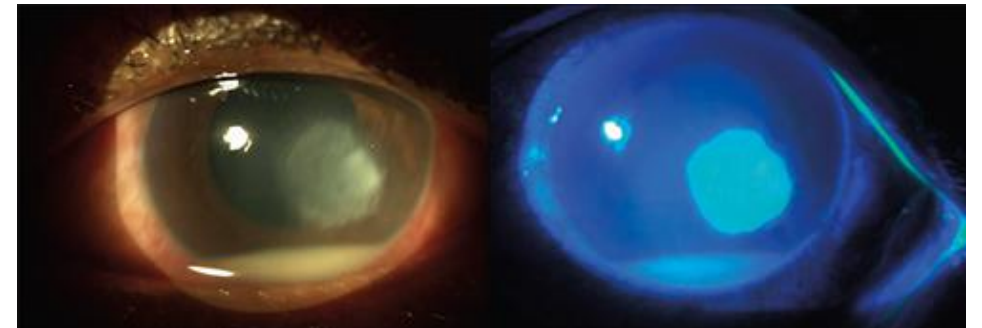
Recurrent corneal erosion

- a recurring loss of epithelial tissue after corneal injury



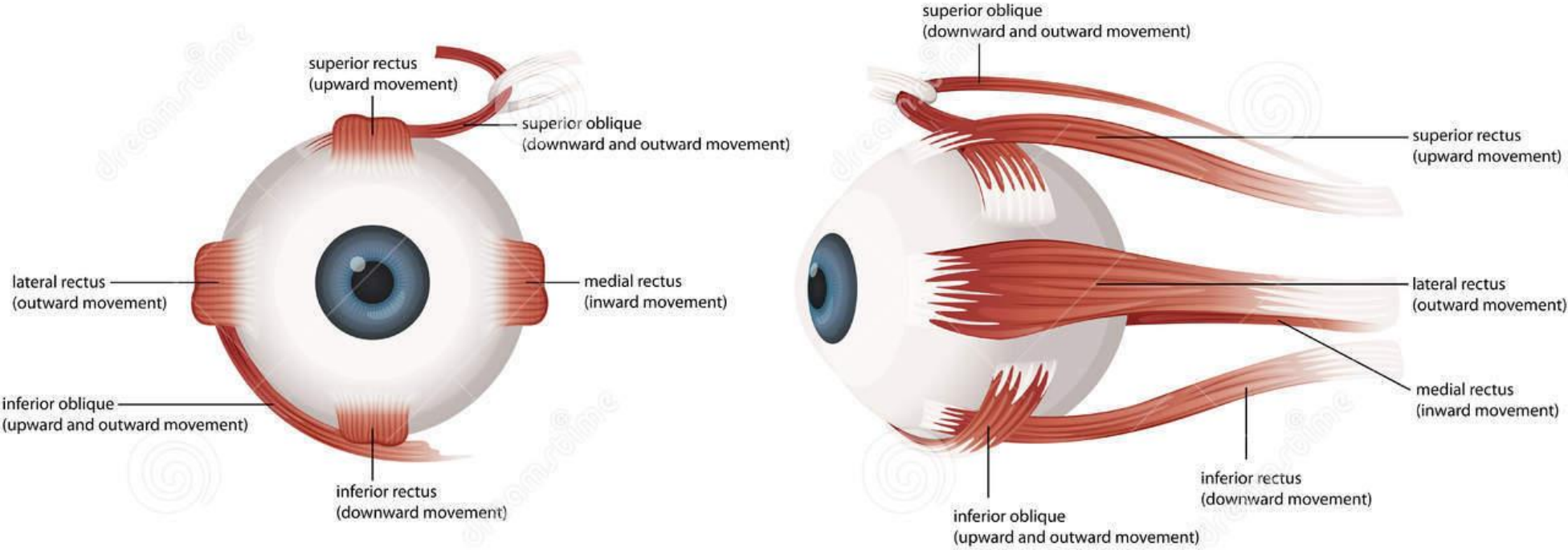
Ulcer – (corneal)

- open corneal tissue as a result of trauma, burns or infection

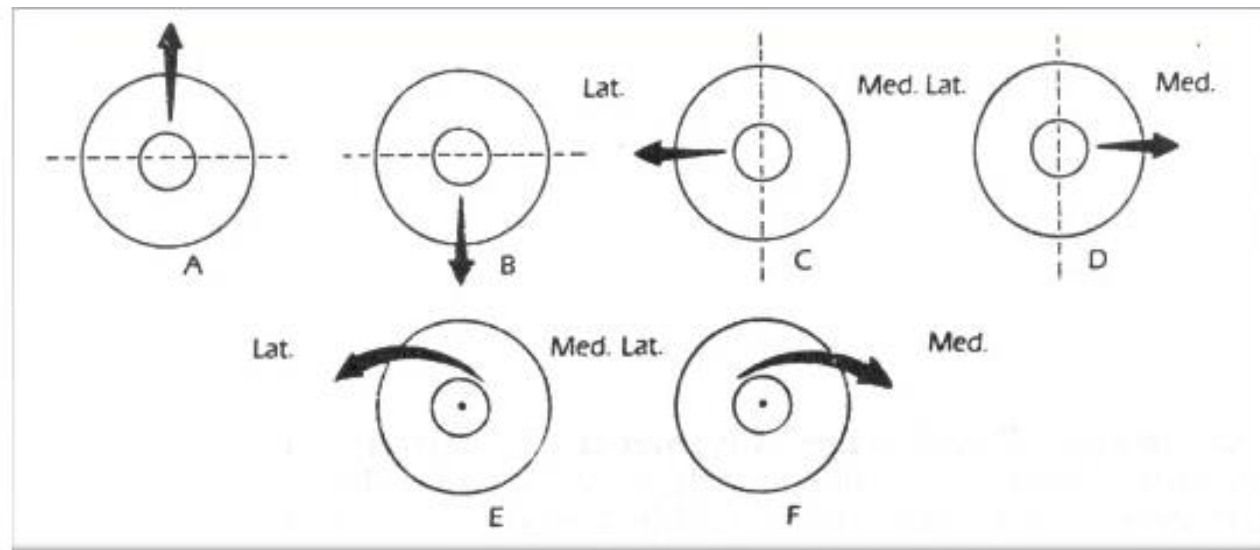


Extrinsic Muscles

Muscles of the Human Eye



Extrinsic Muscles



A- elevation
D- adduction

B- depression
E- extortion

C- abduction
F- intortion

Strabismus

Tropia

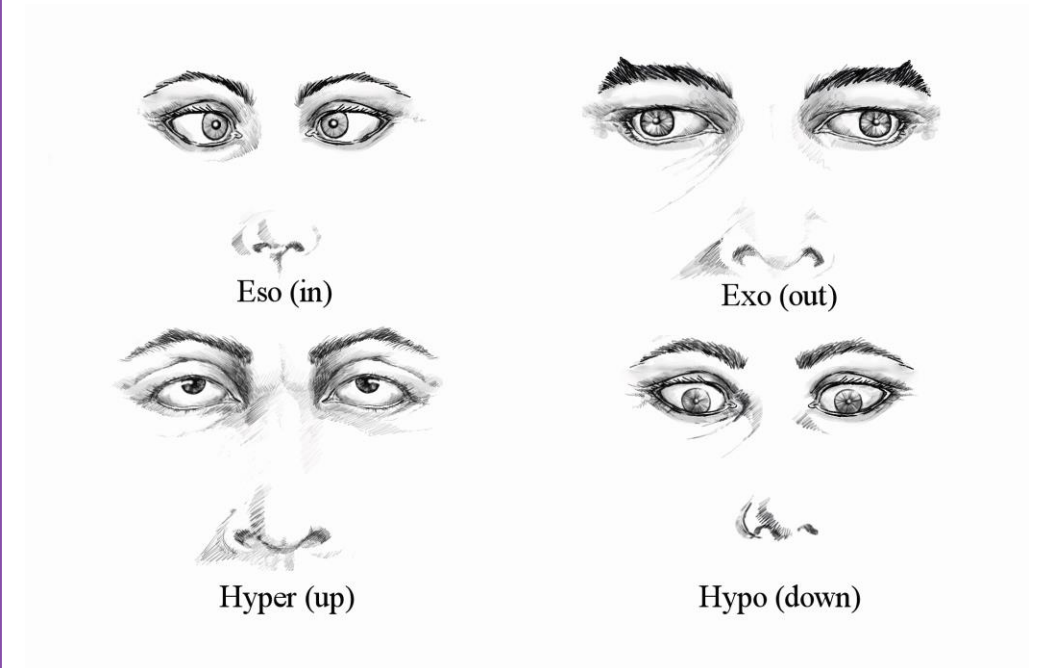
- Always present

Phoria

- Some of the time
 - When the patient is tired or when fusion is broken (you cover an eye and it starts to drift)

Strabismus

- Esophoria or Esotropia medial
- Exophoria or Exotropia lateral
- Hyperphoria or Hypertropia superior
- Hypophoria or Hypotropia inferior



Cranial Nerves

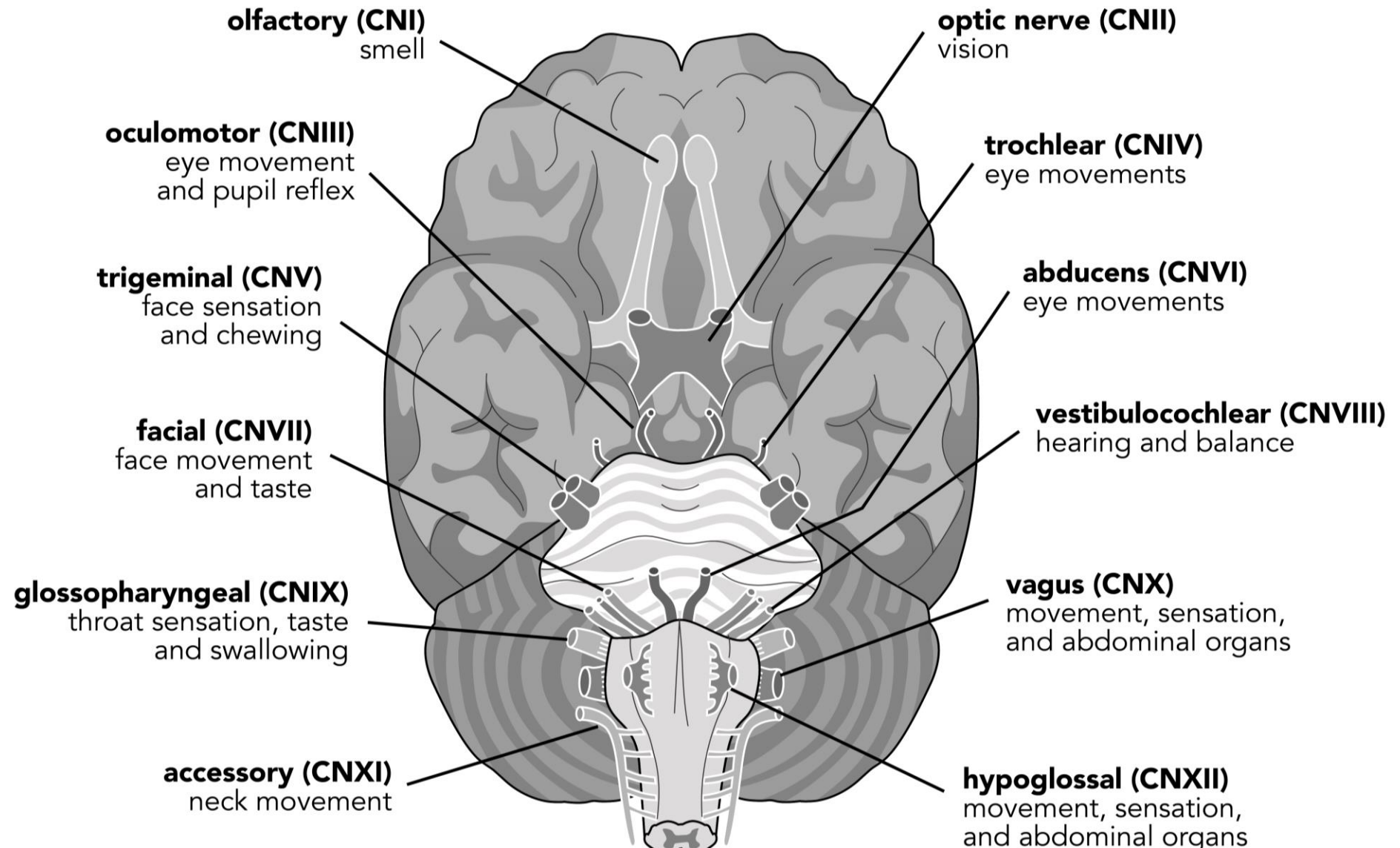
CN II - vision

CN III - eye motility

CN IV - superior oblique eye muscle

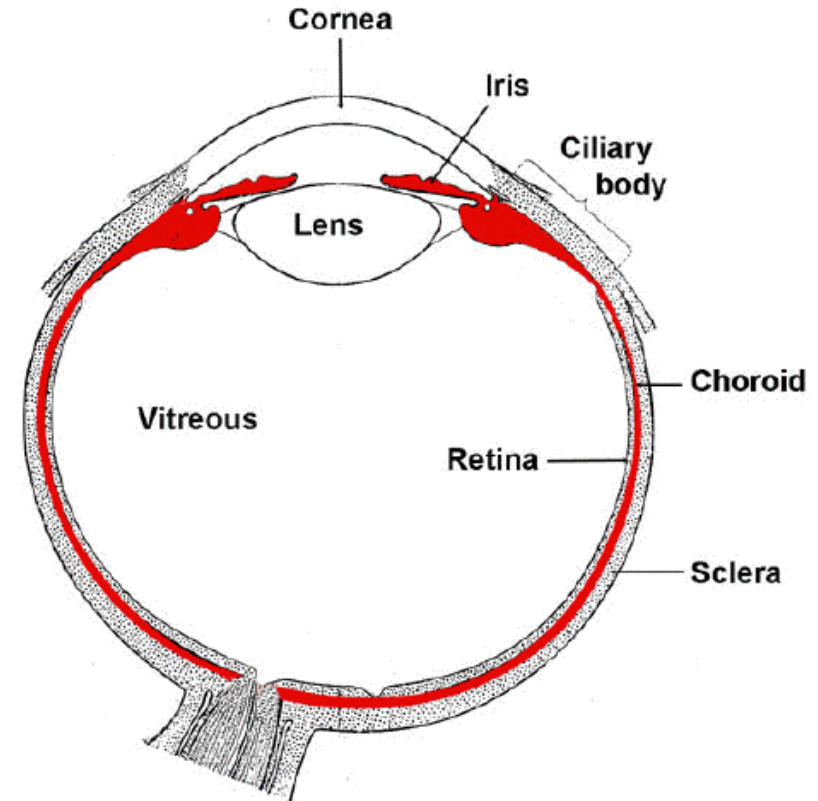
CN VI - lateral rectus eye muscle

CN VII - facial and lacrimal gland



Uveal Tract

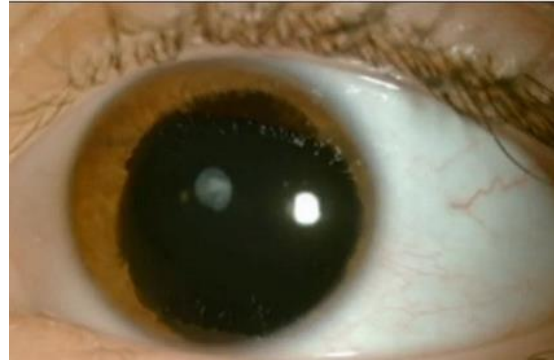- Layer of tissue in between the sclera and retina
- Contains
 - Iris
 - Pigmented filter of light
 - Controls the amount of light that enters the eye through the pupil
 - Ciliary body
 - Produces aqueous humor fluid that fills space in front of and behind iris
 - Contraction controls zonules
 - Choroid
 - Large amount of blood vessels
 - Supports and nourishes the retina



Disorders of the Uveal Tract

Aniridia

- a congenital absence of the iris



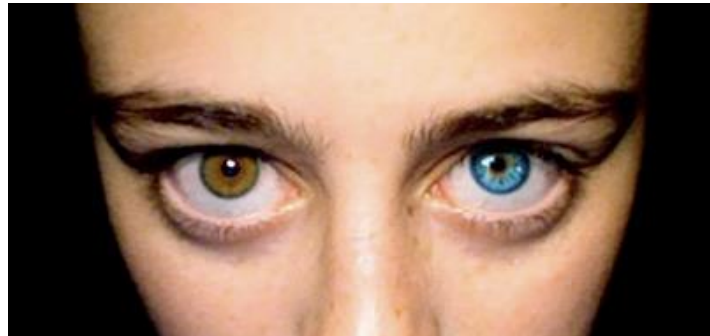Anisocoria

- unequal pupil sizes



Heterochromia

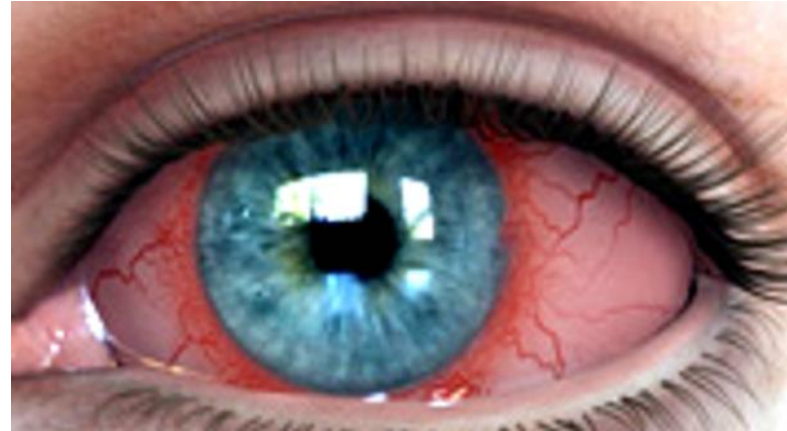
- different colored irides



Disorders of the Uveal Tract

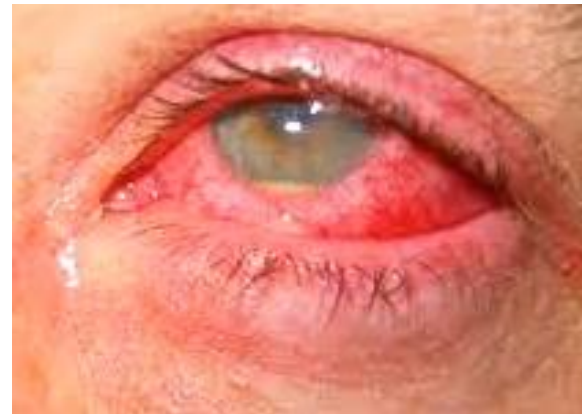Iritis – inflammation of the iris

- Acute pain; red eye
- Blurry vision
- Ciliary flush
- Cells and flare



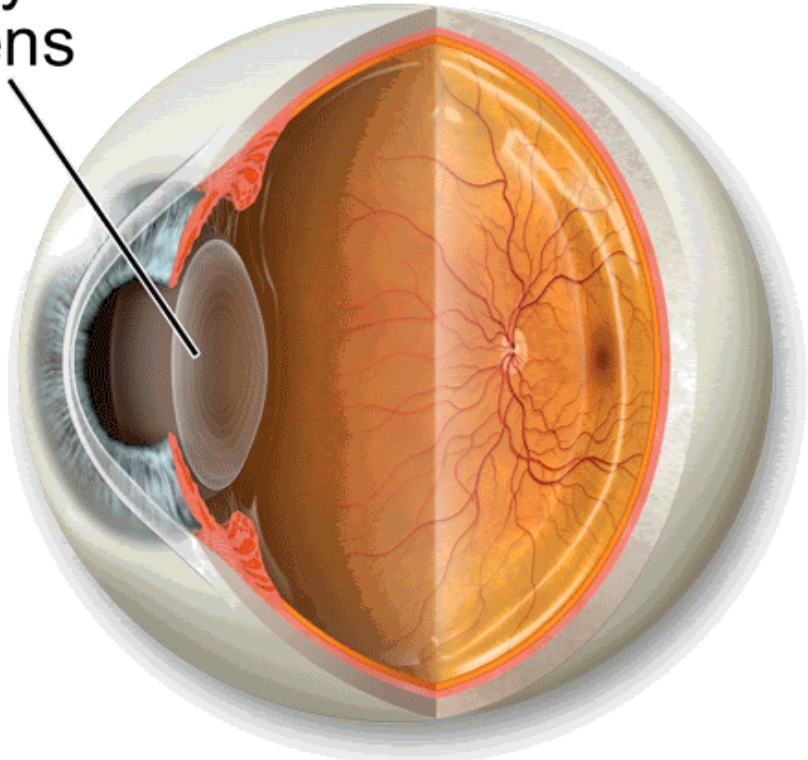
Uveitis – inflammation of the uvea

- Acute pain; red eye
- Blurry vision
- Floaters
- Light sensitivity



Crystalline Lens

Crystalline
Lens



Crystalline Lens

- Crystalline Lens - biconvex, transparent lens
- Approximately 19 D. diopters of focusing power
- Refractive index 1.427n
- Primary function is to focus light on the retina using accommodation
- Accommodation - ability to focus at varying distances
- Attenuates longer Ultraviolet Radiation (UV)

Cataract

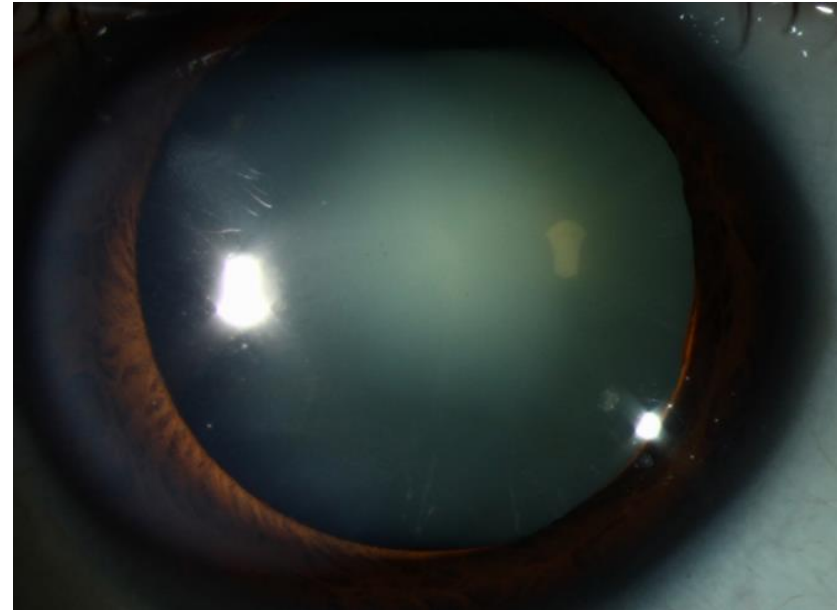
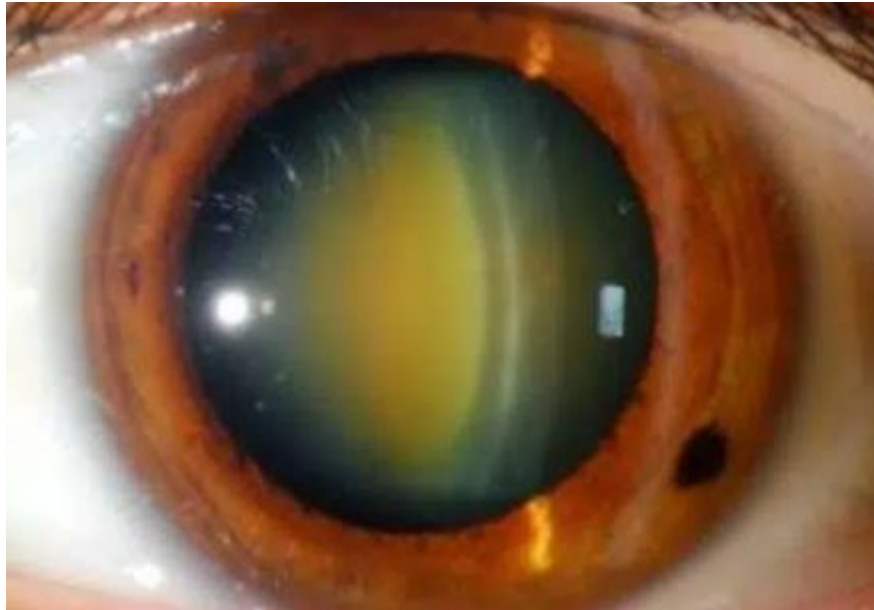
Cataract - opacity of the crystalline lens resulting in reduced vision

- **Nuclear Sclerotic** (NS) — slow progression; lens appears cloudy / hazy. Can be brunescent (brownish color)
- **Cortical** - white edges of streaks similar to spokes on a bicycle wheel; more common in diabetics
- **Posterior Subcapsular** – form on the back of the lens; rapid progression; more common in diabetics or from high doses of steroids

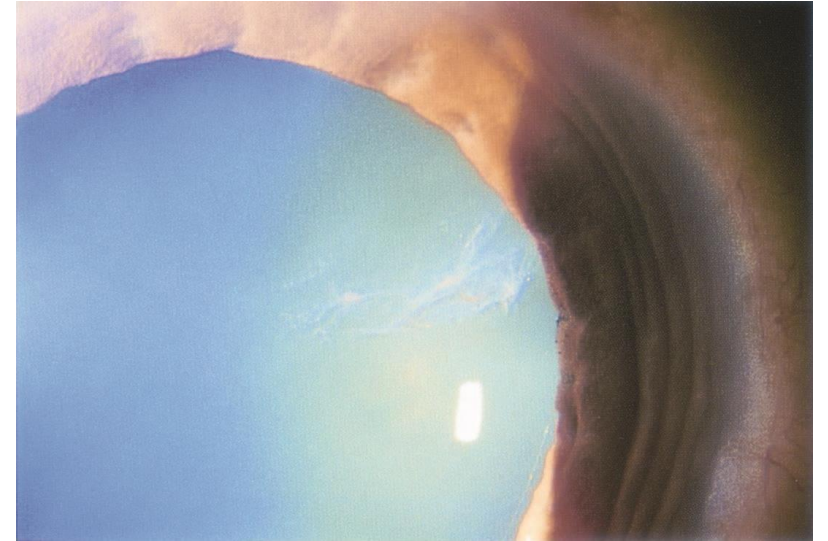
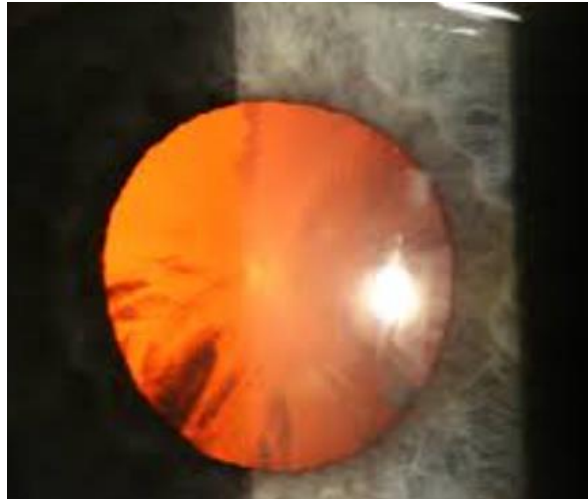
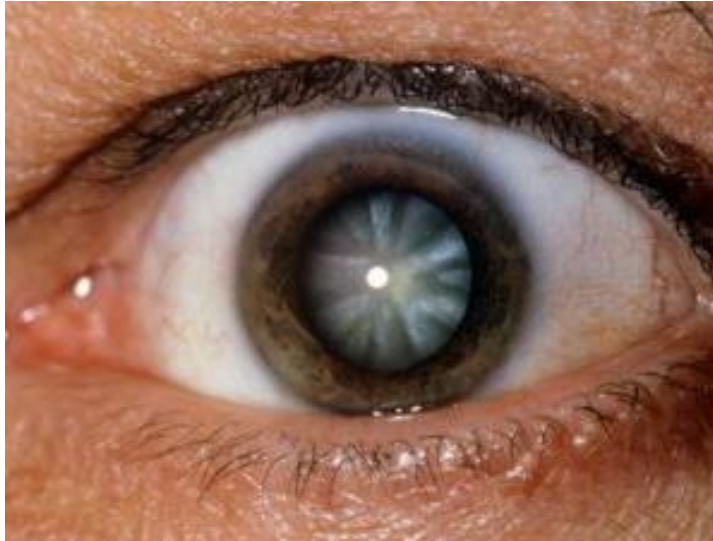Three Categories:

- **Senile** - age related or could be environmental (steroid induced or other)
- **Traumatic** - injury to the crystalline lens (examples: bb gun, hard blow to the eye, arrow or other bruises the lens)
- **Congenital** - occurs at birth

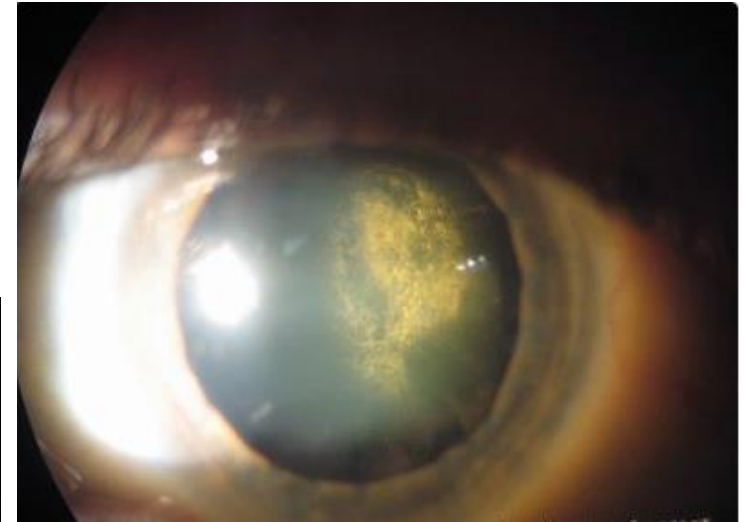
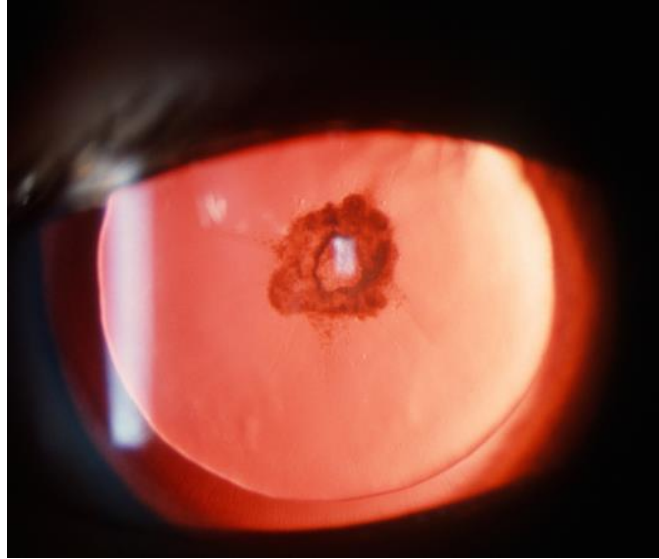
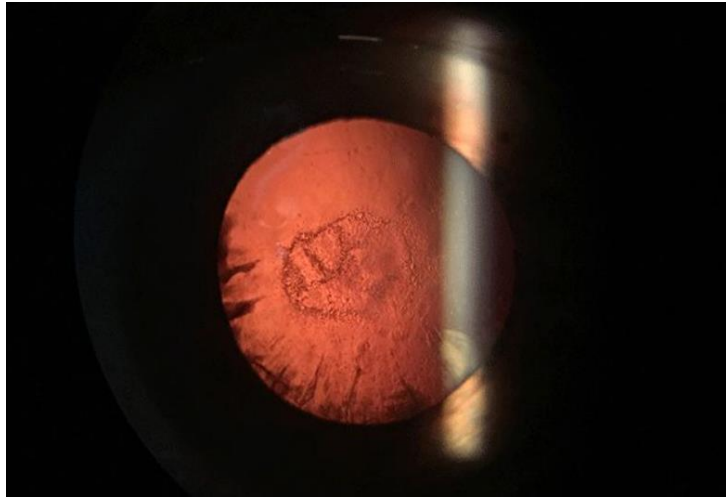
Nuclear Sclerosis



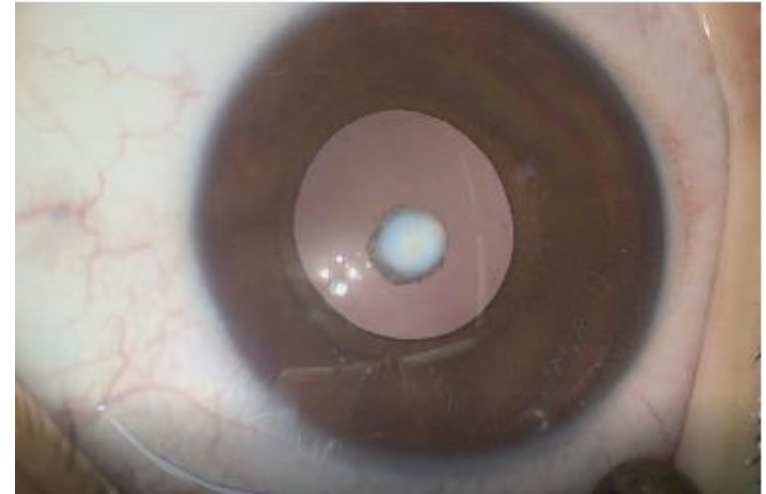
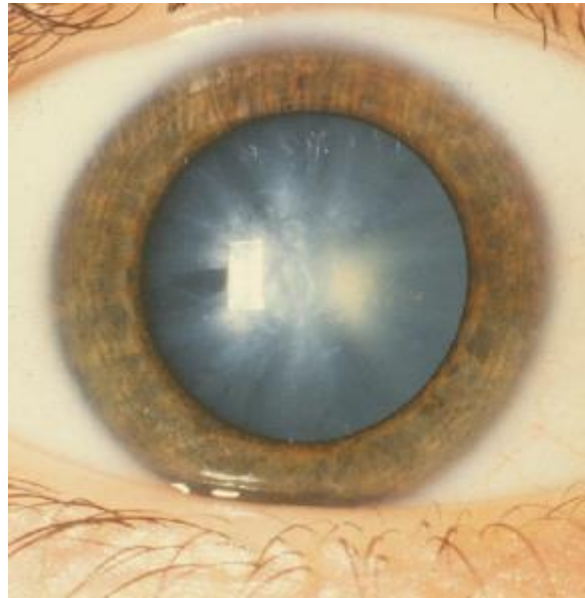
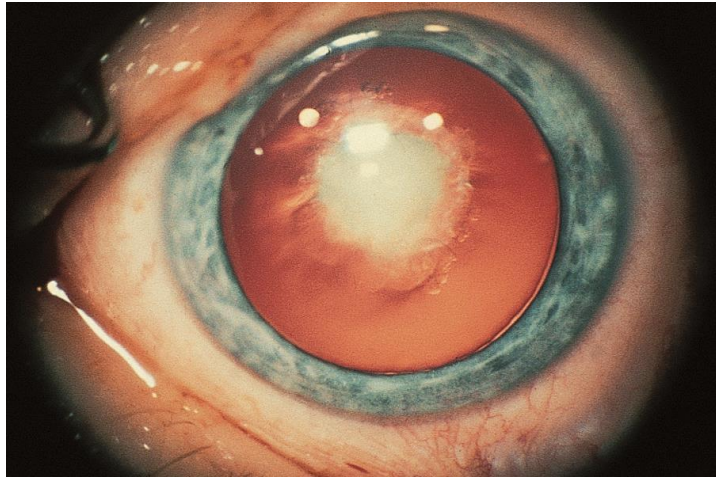
Cortical Cataract



Posterior Subcapsular Cataract (PSC)



Congenital Cataract

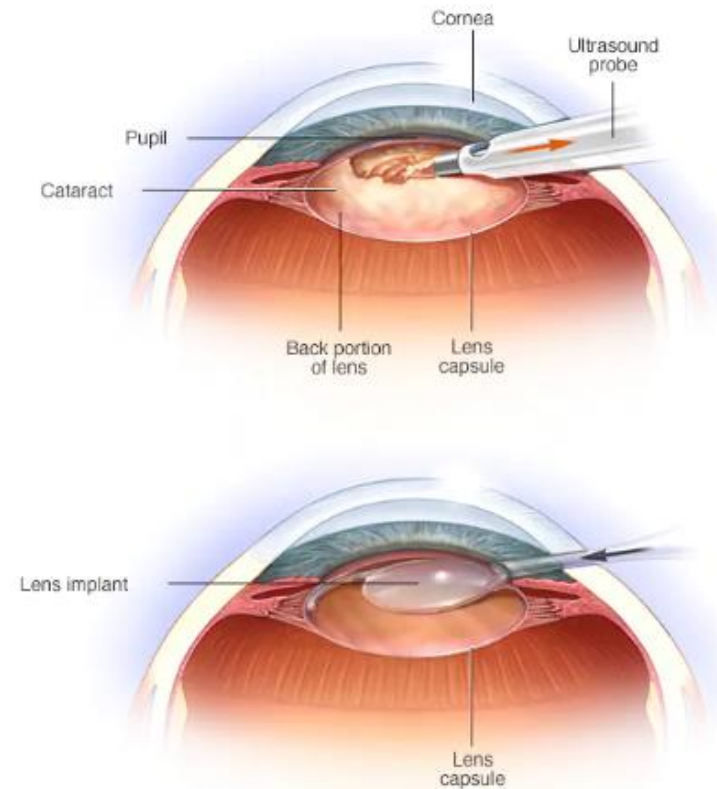


Cataract Surgery

- **Aphakia** (absence of a lens) — crystalline lens, or its nucleus is removed
- **Pseudophakia** (Intraocular Lens or I.O.L.) — cataract surgery is performed. A synthetic lens that is surgically inserted to replace the old lens
- **IOL's** lack accommodative power

Phacoemulsification

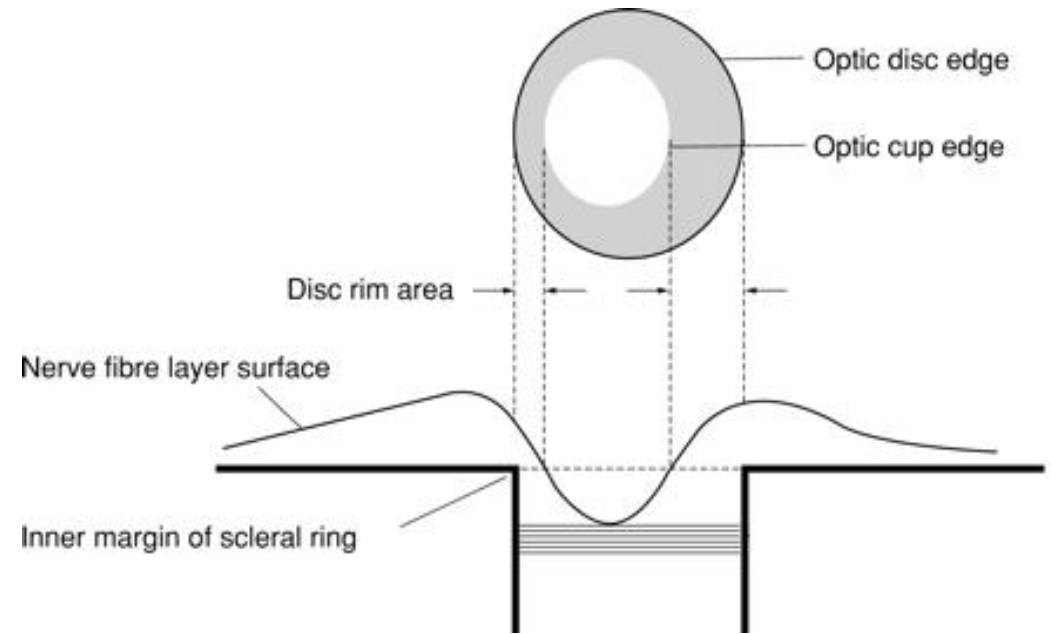
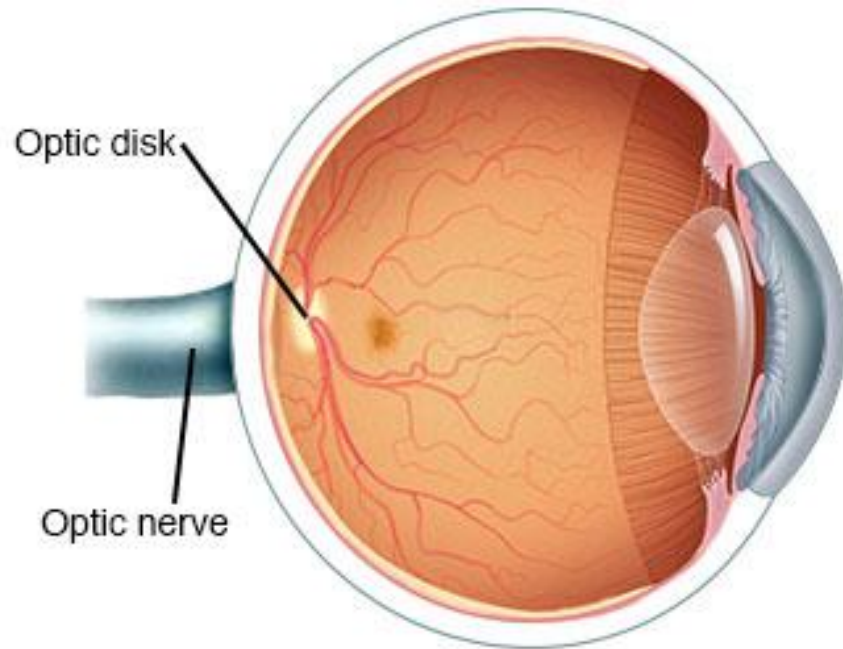
Phacoemulsification (phaco) is method of cataract surgery in which the crystalline lens is emulsified using ultrasonic energy and replaced with an intraocular lens implant (IOL).



Anterior Chamber

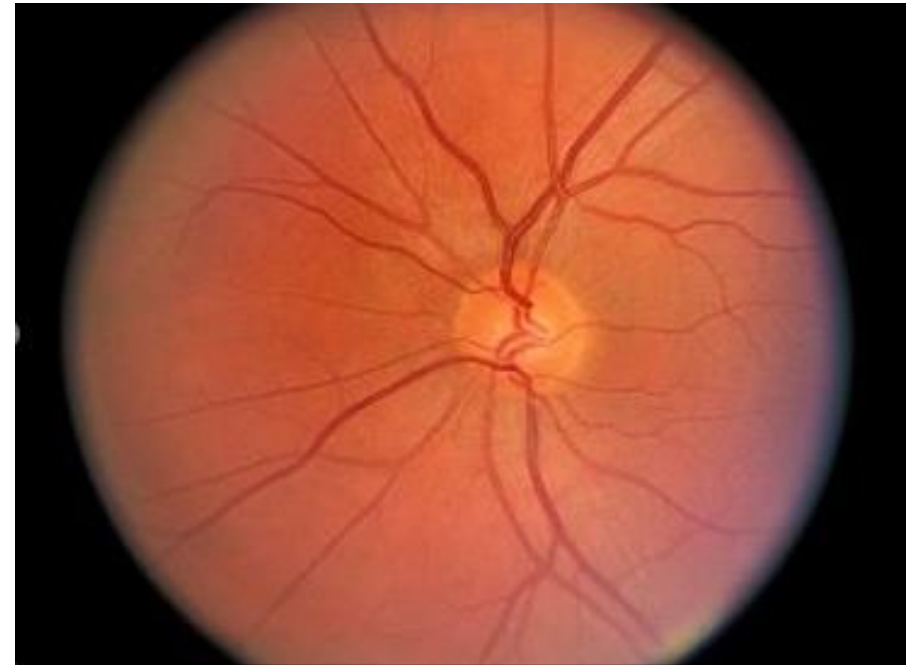- Aqueous Humor - clear fluid behind the cornea in the anterior and posterior chamber
- Refractive index of 1.33n
- Maintains the corneal shape and intraocular pressure
- The Ciliary Body produces the aqueous fluid
- Remains clear due to the filtering through the angle and the “trabecular meshwork”
- Intraocular pressure measured with a tonometer
- Normal pressure is between 15 to 20 Hg (millimeters of mercury)

Optic Nerve & Disc



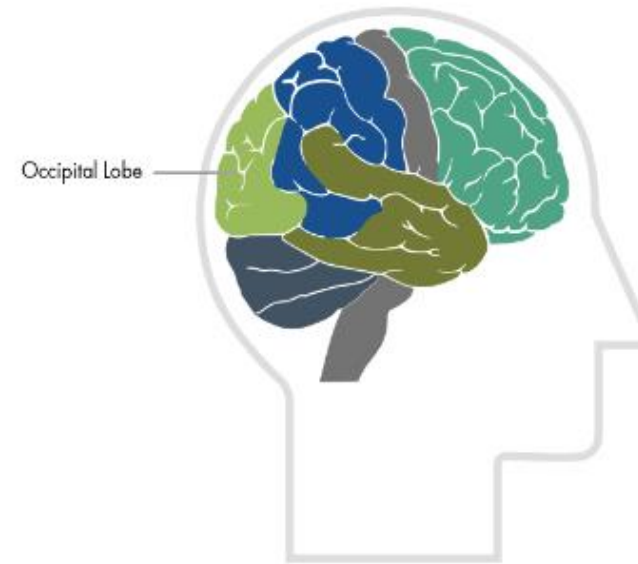
Optic Disc

- **Optic Disc (optic nerve head)** – site where ganglion cell axons accumulate and exit the eye.
- Horizontal Diameter = $\sim 1.7\text{mm}$
- Vertical Diameter = $\sim 1.9\text{mm}$
- Zero photoreceptors = blind spot



Optic Nerve

- **Optic Nerve** - bundle of nerves that carry chemical energy (visual impressions) to the brain
- **Scotoma (blindspot)** — does not contain rods nor cone photoreceptors
- **Occipital Lobe** - area of the brain that interprets images we perceive (vision occurs in the brain not the eye)



Glaucoma

- **Glaucoma** - ocular disease characterized by optic nerve head damage due to excessive intraocular pressure
- Patients with glaucoma require treatment with prescription medication (example: xalatan, latanoprost and others) to lower pressure or may require surgical intervention

NORMAL VISION



ADVANCED GLAUCOMA



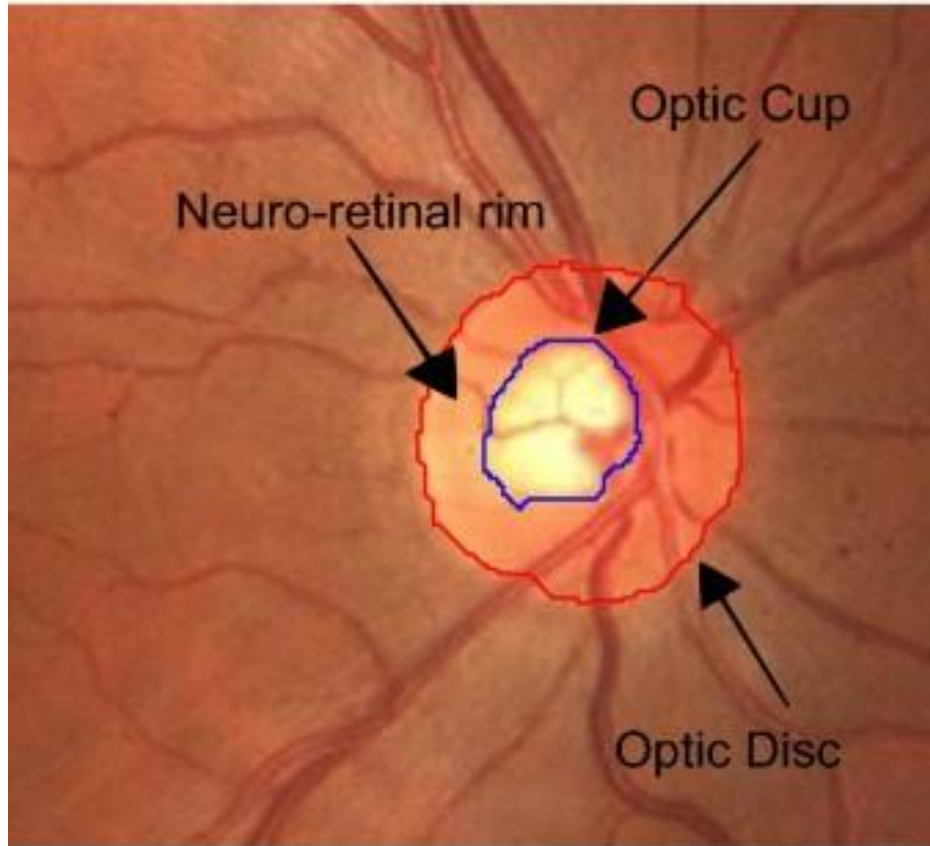
EARLY GLAUCOMA



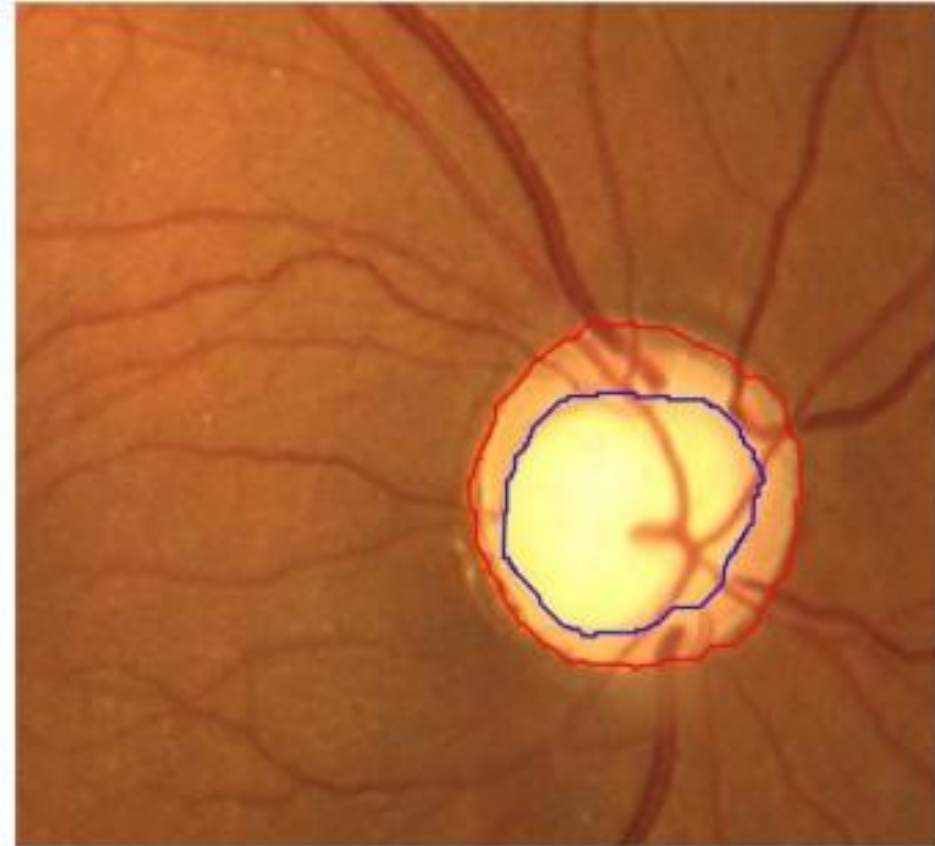
EXTREME GLAUCOMA



Cup to Disc Ratio (.30, .40, etc...)



a



b

Vitreous

- Vitreous Humor - transparent, gelatinous mass in the posterior chamber
- Floaters - separation of the vitreous particles that appear in the line of sight as moving (floating) dark spots

Retina

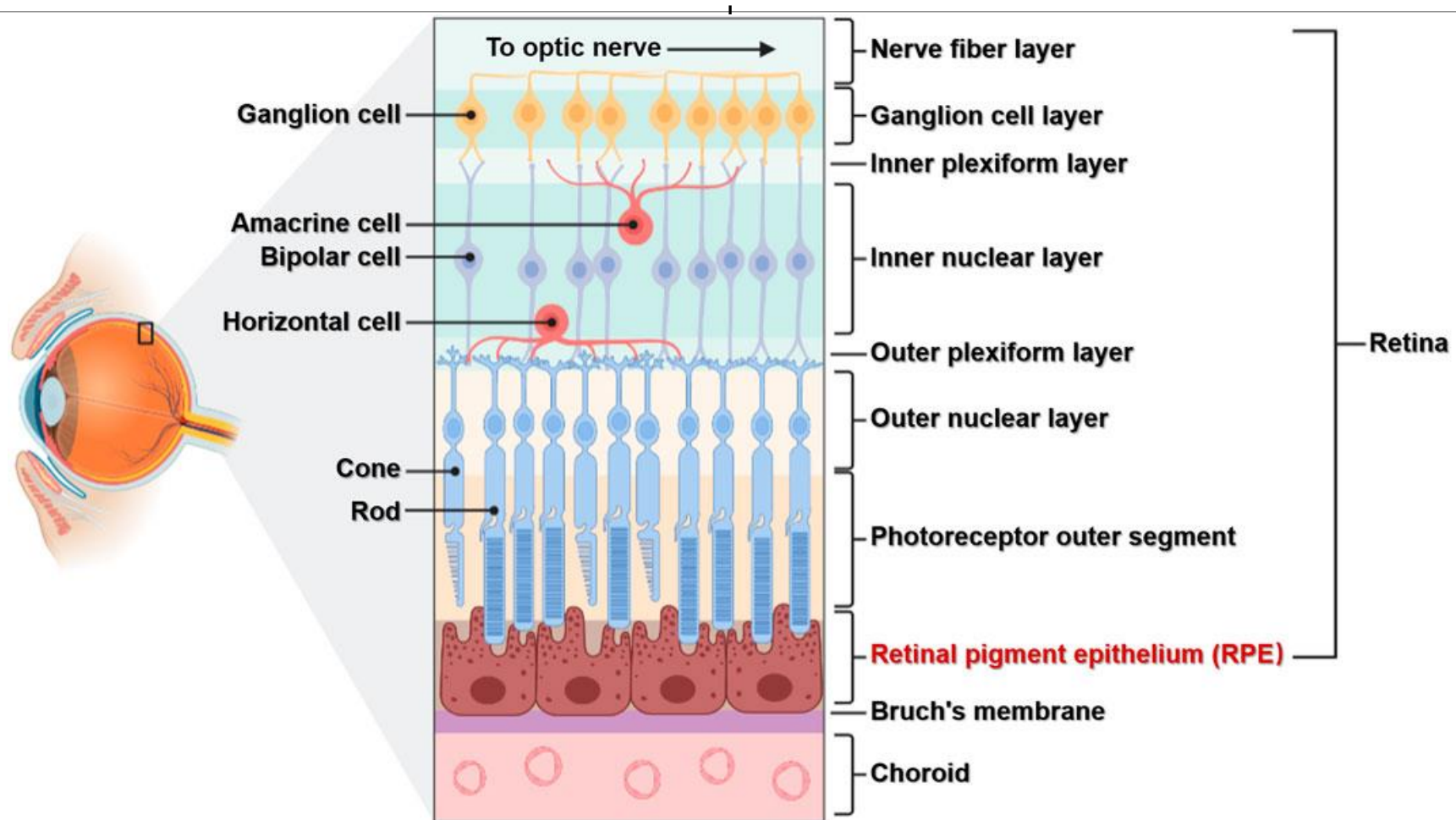
Retina – light sensitive innermost nerve network of the eye

10 layers

Inner coat posterior $\frac{3}{4}$ surface

Contains the macula, rods, cones, and optic disc

Retina Layers



Diseases of the Retina

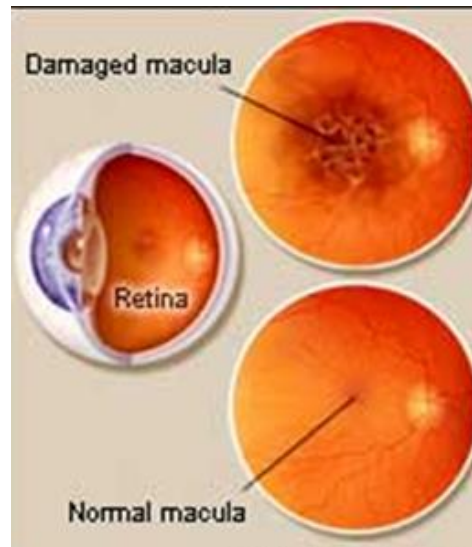Diabetic Retinopathy

- hemorrhaging and vascular changes in the retina associated with diabetes

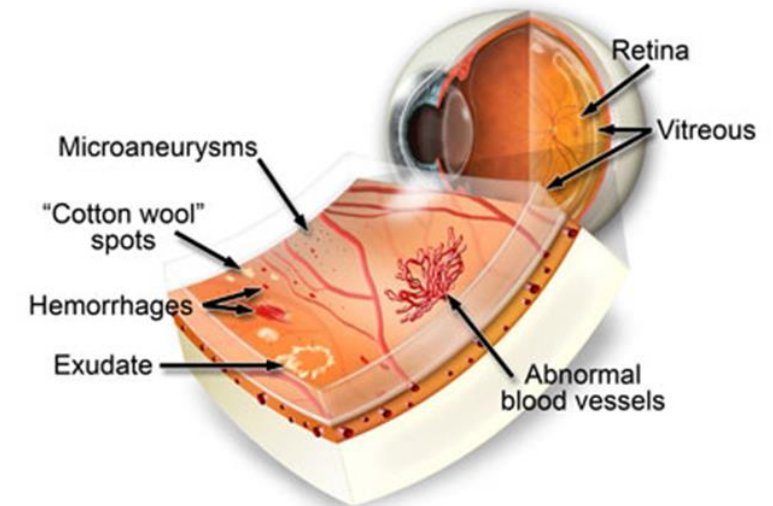


Macular degeneration

- a loss of central vision due to an age related degeneration of the macular region



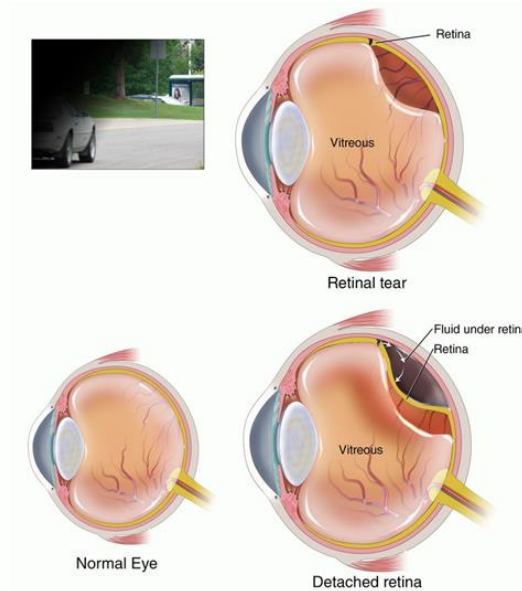
Diabetic Retinopathy



Diseases of the Retina


Retinal detachment

- When the retina tears or loses contact with the choroid



Retinitis pigmentosa

- A hereditary disorder that affects mainly the rods.
- Gradual loss of peripheral vision



Questions

